

Original article

# Ciprofloxacin Affects Sperm Quality and Induces Testicular and Hepatic Injury in Male Mice

Samira Sasi<sup>1\*</sup>, Nagia Alghoul<sup>2</sup>, Sumaia Toumi<sup>1</sup>, Nuri Awayn<sup>3</sup>, Walid Saadawi<sup>4</sup>, Ragil Prastiya<sup>5</sup>

<sup>1</sup>Department of Zoology, Faculty of Science, University of Tripoli, Tripoli, Libya

<sup>2</sup>Biotechnology Research Center, Tripoli, Libya.

<sup>3</sup>Department of Chemistry, Faculty of Science, University of Tripoli, Tripoli, Libya

<sup>4</sup>National Center of Disease Control, Ministry of Health, Tripoli, Libya

<sup>5</sup>Department of Reproduction, School of Health and Life Sciences, Universitas Airlangga, Surabaya, Indonesia

## ARTICLE INFO

Corresponding Email. [samira\\_18\\_3@yahoo.com](mailto:samira_18_3@yahoo.com)

Received: 25-05-2024

Accepted: 02-07-2024

Published: 07-07-2024

**Keywords.** Ciprofloxacin, Testes, Liver, Mice, Fetuses.

This work is licensed under the Creative Commons Attribution International License (CC BY 4.0).

<http://creativecommons.org/licenses/by/4.0/>

## ABSTRACT

Ciprofloxacin (CPFx) is one of a second-generation fluoroquinolones antibiotic and is prescribed a lot for curing bacterial infection. The aim of this study was to investigate of impact CPFx on sperm characteristics, liver DNA and histological structure of liver and testes. Twenty-four male mice aged 7-10 weeks were divided into three groups of eight. The first group (control) was given distilled water. The second and third groups received CPFx with doses 500 and 750 mg/kg respectively. All treatments were administrated orally for 14 days. Three untreated females were put with one treated male for mating. At the end of dosing period, mice were killed, testes and liver were removed and weighed. Sperm parameters, testosterone level and liver DNA were measured. Histopathology of liver and testes was carried out. The results showed that CPFx significantly affected liver DNA, sperm motility and morphology as well as it caused histopathological alterations of hepatic and testicular tissues. Moreover, it led to a significant elevation in the percentage of dead fetuses and also deformity fetuses. The results indicate that CPFx has detrimental effects on sperm quality, liver DNA and histological structure of testes and liver; therefore, it should be used with great caution.

**Cite this article.** Sasi S, Alghoul N, Toumi S, Awayn N, Saadawi W, Ragil Prastiya R. Ciprofloxacin Affect Sperm Quality and Induced Testicular and Hepatic Injury in Male Mice. *Alq J Med App Sci.* 2024;7(3):477-483.

<https://doi.org/10.54361/ajmas.247308>

## INTRODUCTION

Antibiotics are the most prescribed medications for treatment of different types of infection, they were used for treating the infection of genital tract which can affect fertility in male [1]. Fluoroquinolones are one of the most antibiotics used against the bacterial infection that infect humans and animals [2]. In addition, they have detrimental impacts on reproductive system and some of fertility parameters [3].

Ciprofloxacin (CPFx) represents a second-generation fluoroquinolone, and has more than 300 different names [4], moreover, it is the most commonly known antibiotics used for curing of bacterial infection which affects the joints, bones, urinary and respiratory tracts [5]. Also, it can inhibit the growth of cultured mammalian cells [6], type I topoisomerase and DNA gyrase which are required for DNA replication in prokaryotic [5], as well as it induces cellular damage and chondrotoxicity [7]. CPFx can be transported to seminal fluid leading to genetic changes in sperm. Several studies indicated that CPFx causes an increase in DNA fragmentation with reduction in sperm chromatin quality [1], histological alterations of testis [8-10], and also it has toxic effects on reproductive system in male rats [11], liver [12,13],

central nervous system and gastrointestinal canal [5]. A previous study showed that treatment of male mice with CPFx at doses 206 and 412 g/kg for 45 consecutive days led to DNA damage and chromatin abnormalities, as well as, low fertilization rate and retarded embryonic development [14]. The aim of this study was to evaluate effect of CPFx on sperm characteristics, liver DNA and histological structure of testis and liver.

## **METHODS**

### ***Drug***

Ciprofloxacin (CPFx) was purchased in form of coated tables, from the pharmacy. CPFx 500 mg, Bristol laboratories Ltd, its empirical formula is  $N_{17}H_{18}FN_3O_3$  and its molecular weight is 331.4 g/mol.

### ***Animals and experimental design***

Twenty-four male mice were used in this study, their ages 7-10 weeks and their weights 25-29g. They were bred in the animal house/ Department of Zoology/ Faculty of Science/ University of Tripoli in clean suitable environmental conditions and exposed to 12-hour light/ dark cycle and given the food and water. Mice were divided into three groups, each group consisting of eight animals, the first group (control) was given distilled water orally, while the second and third groups received CPFx at doses of 500 and 750mg/kg respectively for 14 days.

### ***Sample collection***

At the end of the dosing period, mice were weight and killed by cervical dislocation, liver and testes were extracted and weighed, then, kept in formalin (10%) for histological studies.

### ***Sperm count and motility assessment***

The vas deferens were removed and minced with forceps in petri dish containing 1 ml of normal saline then, incubated at 37 °C for 10 min. Sperm count was done by placing drops of sperm suspension into Neuber's counting chamber. The sample was allowed to stand for 5 min and observed under the microscope at 400 x magnification. Sperm motility was assessed by placing a drop of sperm suspension on the slide, covered with coverslip and observed under the microscope at 400 x magnification.

### ***Sperm morphology***

A drop of sperm suspension was placed on clean glass slides and air-dried, after that, stained with 1% eosin for 10 min. 200 sperm were examined at 400x for determination abnormal sperm.

### ***Histopathology***

Liver and testes tissues were fixed in 10% formalin solution. The tissues were passed through graded series of ethanol, cleared in xylene, embedded in paraffin. The sections were cut with thickness a 5 µm using rotatory microtome and stained with eosin and hematoxylin, after that, examined under the microscope and photographed.

### ***Testosterone measurement***

Blood samples were collected from facial vein. Serum was separated, after that, centrifuged at 3000 rpm for 10 minutes to determine the level of testosterone hormone by ELISA technique.

### ***DNA concentration in liver***

A part of liver from the control and treated groups was preserved at (-80 C<sup>0</sup>), after that, DNA was extracted by QI Aamp DNA mini-Kit (Qiagen). DNA concentration was measured using Nano drop device.

### ***Effect of CPFx on fetuses.***

Treated male mice were placed with untreated female mice together (1:3) in a single cage overnight for mating, when vaginal plug was observed, that day was considered as day zero of gestation. On day 18<sup>th</sup> of gestation, the females were killed, the fetuses were removed and the percent of deformity fetuses and dead fetuses were determined.

### ***Statistical analysis***

The analysis was performed by SPSS (version 20). Data were analyzed by ANOVA test and followed by Duncan's Post hoc test. The results were expressed as mean ± SD, P value < 0.05 were considered significant.

### ***Ethical approval***

Ethical approval for the experimental protocol of the study was obtained from the Ethics Committee of University of Tripoli (Ref No; SREC 19 -2022).

## RESULTS

### Effect of CPFx on body weight

Our results revealed that exposure of mice to CPFx caused non-significant decrease ( $P > 0.05$ ) in body weight of treated groups (Table 1).

**Table 1. Body weight in mice exposed to CPFx.**

Parameters	G1 (control)	G2	G3
Body weight (g)	28.37 ± 2.69	28.17 ± 0.98	26.50 ± 0.55

*Values are represented as mean ± SD.*

### Semen analysis in mice exposed to CPFx.

Administration of 500 and 750 mg/kg of CPFx to male mice resulted in a significant decline ( $P < 0.05$ ) in sperm motility of treated groups compared to the control group. On the other hand, the percentage of abnormal sperm in the treated groups increased significantly ( $P < 0.05$ ) than that in the control group. Non-significant difference was found in sperm count ( $P > 0.05$ ) between the treated and control groups (Table 2).

**Table 2. Sperm parameters in mice exposed to CPFx.**

Groups	Abnormal sperm%	Sperm count ( $10^6$ /ml)	Sperm motility
G1 (control)	0.33 ± 0.03	28.75 ± 19.16	0.87 ± 0.13
G2	0.77 ± 0.15*	22.83 ± 14.55	0.62 ± 0.13*
G3	0.72 ± 0.10*	21.33 ± 12.33	0.74 ± 0.03*

\* ( $P < 0.05$ ) significantly different from the control, data are represented as mean ± SD.

### Evaluation of testosterone hormone.

The results of the current study showed that there is no significant difference ( $P > 0.05$ ) in the level of testosterone of the treated groups in comparison to the control group (Table 3).

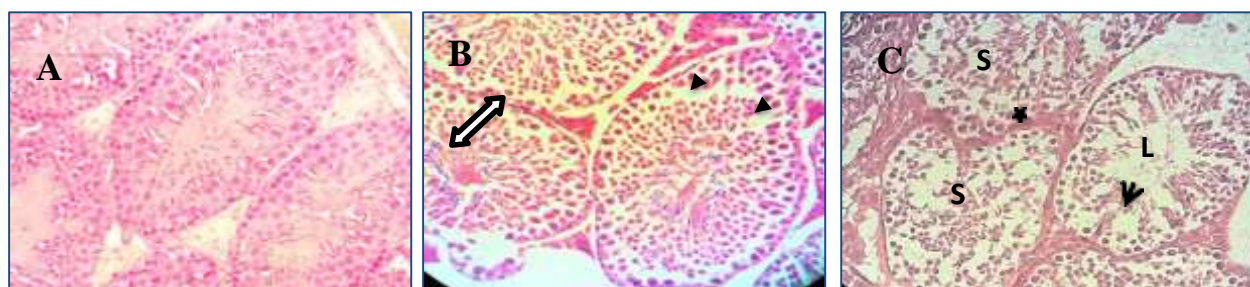**Table 3. Testosterone level in mice exposed to CPFx**

Hormone	G1 (control)	G2	G3
Testosterone (ng/ml)	0.65 ± 1.03	1.67 ± 1.90	1.60 ± 1.36

*Values are represented as mean ± SD.*

### Histopathological findings of testes

The testicular tissues of control mice showed the presence of a normal testicular structure and regular seminiferous tubular morphology with normal spermatogenesis (Figure 1A). testicular tissues from the group exposed to 500 mg/kg of CPFx revealed loss of some spermatogenic cells and existence gaps between them as well as disorganization of germinal epithelium in some seminiferous tubules (Figure 1B). while 750 mg/kg treated mice demonstrated disorganized of spermatogenic epithelium, a thickness in basement membrane, sloughing of germinal epithelium, vacuolization of germ cells cytoplasm as well as absence of spermatozoa in the lumen of some seminiferous tubules (Figure 1C).



**Figure 1.** A photomicrograph of a testicular tissue from the control mice (A) showing the normal structure of seminiferous tubules and the interstitial spaces also appear normal. (B) a photomicrograph of a testicular tissue of 500 mg/kg CPFx treated mice showing disorganization of germinal epithelium in some seminiferous tubules (double head arrow) and loss of some spermatogenic cells (black triangle). (C) a photomicrograph of a testicular tissue of 750 mg/kg CPFx treated mice showing a thickness in basement membrane (star), sloughing of germ cells into tubular lumen (S), vacuoles (head arrow) and absent of sperm in lumen (L). (H & E 40 x)

**DNA concentration hepatic tissues of mice exposed to CPFx.**

The statistical data in (Table 3) demonstrated that DNA concentration significantly declined ( $P < 0.05$ ) in CPFx treated groups compared with the control group.

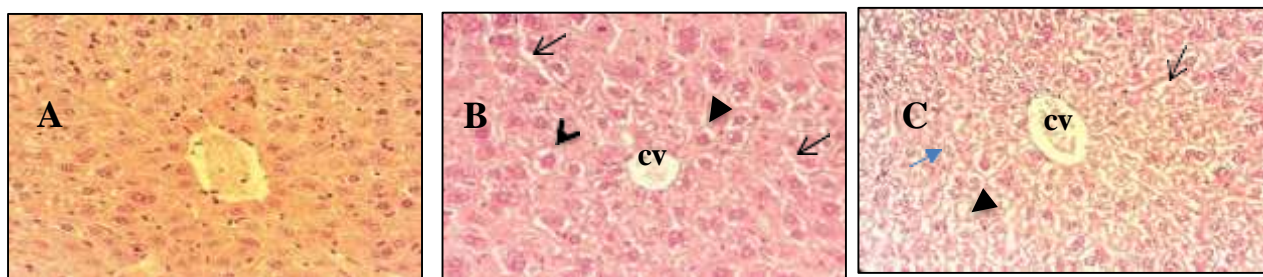
**Table 3. liver DNA in mice exposed to CPFx**

Parameter	G1 (control)	G2	G3
DNA concentration (ng/ml)	315.88 ± 307.12	115.28 ± 97.96*	28.84 ± 18.46*

\* ( $P < 0.05$ ) significantly different from the control, data are represented as mean ± SD.

**CPFx induces histopathological changes in hepatic tissues.**

No pathological changes have been observed on liver of control mice. The histological examination of liver tissues in control exhibited normal structure of hepatocytes, blood sinusoids and portal areas (Figure 2A). In 500 mg/kg CPFx treated mice, the histological examination of hepatic tissues showed vacuoles in cytoplasm of some hepatocytes, loss of normal arrangement of some hepatocytes and congested central vein (Figure 2B). the hepatic tissues of mice received 750 mg/kg CPFx treatment demonstrated alterations represented by widening in some of hepatic sinusoids, vacuoles in cytoplasm of hepatic cells, pyknotic in nuclei of some hepatic cells and dilated, congested central vein. In addition, sections exhibited some hepatocytes with mitotic figures (Figure 2C).



**Figure 2. A photomicrograph of liver in the control group (A) showing normal histological architecture of hepatic tissues with intact cells forms cords around the sinusoids. (B) a photomicrograph of liver in 500 mg/kg treated mice showing loss of the normal arrangement of some hepatocytes with slightly dilated sinusoids (arrow), pyknotic nuclei (head arrow), some cells show intracytoplasmic vacuoles (black triangle) and congested central vein (cv). (C) a photomicrograph of liver in 750 mg/kg treated mice showing dilated, congested central vein (cv), vacuoles of cell cytoplasm (black triangle), dilated sinusoids (arrow) and mitotic figures (blue arrow) (H & E 40 x).**

**Effect of CPFx on the fetuses**

The findings in (Table 4) showed that CPFx led to a significant rise ( $P < 0.05$ ) in the percent of deformity fetuses and also dead fetuses of untreated females impregnated by treated males.

**Table 4. Effect of CPFx on fetuses.**

Parameters	G1 (control)	G2	G3
Deformity fetuses%	0.10 ± 5.02	0.25 ± 7.30*	0.31 ± 10.42*
Dead fetuses %	0.07 ± 3.10	0.20 ± 4.53*	0.22 ± 5.13*

\* ( $P < 0.05$ ) significantly different from the control, data are represented as mean ± SD, no of females: 6 for each group, female mice were untreated.

**DISCUSSION**

The results of current study indicated that CPFx administration to mice orally caused a significant decrease in sperm motility of treated mice compared to the control group. This result was in accordance with previous studies reported that CPFx led to a reduction in sperm motility [11,15]. Another study showed that oral treatment of rats with CPFx caused a marked decline in sperm motility [1]. Demir *et al* [8] recorded a marked reduction in sperm motility in rats treated with CPFx for 10 days. This effect on sperm motility may be due to interference of CPFx in energy production process required for motility [16] or its effects on structure and function of  $Ca^{2+}$  ions that are in cell membrane of sperm [17].

In this study, we found significantly elevation in the percent of abnormal sperm in the treated groups with CPFx. This result supported by a previous findings obtained by Abd *et al* [1] who reported that administration of CPFx to rats with 80 mg/kg for 28 days resulted in an increase in the percent of abnormal sperm. Another research showed a significant decline in normal sperm after CPFx treatment in asthenozoospermia men [18].

Our results also demonstrated that testosterone level was not affected by CPFx. Similarly, Abd *et al* [1] illustrated that treated rats with CPFx either 40 mg/kg/day or 80 mg/kg/day for either 14 days or 28 days did not affect the level of testosterone hormone. However, other investigators have found a decrease in testosterone level in male rats [3, 9], and male guinea pigs [19]. Zobeiri *et al* [14] stated that CPFx at doses 206 and 412 mg/kg for 45 days reduced the level of testosterone hormone. This variation between the studies could be attributed to many factors such as the dose or route of administration or duration of exposure.

The histological sections from testes of the treated groups revealed disorganized of spermatogenic epithelium, intracellular vacuolization and sloughing of germinal epithelium. Similar results have shown that CPFx has negative effects on testicular tissues of rats [11,20]. Moreover, it was reported that treatment of rats with CPFx led to histopathological disturbances in seminiferous tubules and interstitial tissues [8, 9]. In supported of our findings, Mojinyinola *et al* [10] observed that administration of CPFx to rats for three weeks resulted in deterioration of testicular cytoarchitecture. Testicular damages could be explained by decreased level of LH and FSH [14] or an increase in apoptosis of germ cells in testes [11] by increasing of free radicals' production [21]; this increase will induce DNA single strand breaks and chromosomal aberrations as revealed in some in vitro genotoxicity studies [22,23].

A significant decrease in liver DNA of treated mice was observed in the present study. Similar result was recorded by Shihab and Sadek [24] who elucidated that treated rats with CPFx resulted in DNA damage in liver, bone marrow and spleen. In addition, Gurbay *et al* [7] demonstrated that CPFx induced DNA damage in primary culture of rat astrocytes. Furthermore, our results were in accordance with other studies showed DNA damage and abnormalities of chromatin of sperm following exposure to CPFx in mice [14] and rats [1]. It was suggested that DNA damage may be attributed to oxidative stress by generation of free radicals [7] which can attack DNA leading to mutation [25].

Regarding to various pathological changes observed in the liver of mice exposed to CPFx in this study were similar to the findings of Taslidere *et al* [26] who noted that CPFx caused sever histopathological changes in liver of rats. In supported to our results Chana and Janjua [27] recorded many damages in liver included decreased numbers of hepatocytes, dilated sinusoids and pyknotic hepatocyte nuclei. Also, Sabeeh *et al* [13] found that treatment of rats with 100 mg/kg of CPFx for 30 days caused damage of the liver tissue. Another research has shown that administrate of CPFx to rats for three weeks led to severe hepatic steatosis [10]. Hepatic damage induced by CPFx might be attributed to oxidative stress by increasing of free radicals' production [21, 28] or decreased antioxidants levels [21].

The obtained results in this study revealed significantly rise in the percent of deformity fetuses and dead fetuses. These findings were in accordance with the results of previous studies reported that women exposed to CPFx caused teratogenic effects during pregnancy [29, 30]. Siddiqui and Nagui [31] found that CPFx has detrimental impact on fetuse rats. Fetal loss could be caused the complete damage of DNA while, malformations may be induced by partial damage of DNA [32], DNA damage induced by CPFx could be explain its ability to producing free radicals [7] which can attack DNA [33].

## CONCLUSION

The findings of this study have shown that administration of CPFx at doss (500 & 750 mg/kg) to male mice for 14 days led to detrimental effects on sperm motility and morphology, liver DNA, testicular and hepatic tissues as well as it caused increasing in the percent of deformity fetuses and also dead fetuses. So, it should be used with great caution.

## Acknowledgments

The authors are grateful to Department of Zoology, Faculty of Science, University of Tripoli for providing the laboratories facilities for this investigation.

## Conflict of Interest

The authors declare that there is no conflict of interest.

## REFERENCES

1. Abd AH, Al-Dujaily SS, Al-Saray D A. Effects of Ciprofloxacin on Male Fertility Parameters and Sperm DNA Integrity in Rats. Iraqi J Med Sci. 2018;16(4):378-384

2. Papich M, Riviere J. Fluoroquinolones antimicrobial drugs. In: Adams HR, editor. *Veterinary Pharmacology and Therapeutics*. 5th ed. Iowa: The Iowa State University Press. 2005; pp. 898–917.
3. Iqbal R, Iqbal S, Anjum S. Effect of Quinolones on Serum Testosterone Level in Male Albino Rats. *Annals*. 2017;23(1):29-33.
4. de Almeida MV, Saraiva MF, de Souza MV, da Costa CF, Vicente FR, Lourenço MC. Synthesis and antitubercular activity of lipophilic moxifloxacin and gatifloxacin derivatives. *Bioorg Med Chem Lett*. 2007 Oct 15;17(20):5661-4.
5. Sharma PC, Jain A, Jain S, Pahwa R, Yar MS. Ciprofloxacin: review on developments in synthetic, analytical, and medicinal aspects. *J. Enzyme Inhibition. Med Chem*. 2010;25(4): 577-589.
6. Herold C, Ocker M, Ganslmayer M, Gerauer H, Hahn EG, Schuppan, D. Ciprofloxacin induces apoptosis and inhibits proliferation of human colorectal carcinoma cells. *British J Cancer*. 2002;86(3):443-448.
7. Gurbay A, Gonthier B, Signorini-Allibe N, Barret L, Favier A, Hıncal F. Ciprofloxacin-induced DNA damage in primary culture of rat astrocytes and protection by vitamin E. *Neurotoxicol*. 2006;27(1):6-10.
8. Demir A, Türker P, Şırvancı S, Önel FF, Findik A, Arbak S, Tarcan, T. the effects of acute epididimorchitis and ciprofloxacin treatment on testicular histo- morphology and sperm parameters in rats. *European Urology Supplements*. 2006; 5(2): 214.
9. Mokhmar H, Kandiel M, Amin A, Elsayah H, EL-Mahmoudy A. Ciprofloxacin and levofloxacin adversely affect male infertility indicated by pharmacological, andrological and pathological evidence. *Int J Basic Clin Pharmacol*. 2020; 9(2): 353-360.
10. Mojoyinola A, Ishaya H, Makena W, Jacob C, Jonga U, Anochie V, Denis EW, Gadzama MN. Protective effect of ciprofloxacin-induced oxidative stress, testicular and heptorenal injury by *Citrullus lanatus* L (water melon) seeds in adult Wister rats. *South African J Bot*. 2023;156: 365-375.
11. Khaki A, Heidari M, Ghaffari-Novin M, Khaki A. Adverse effects of ciprofloxacin on testis apoptosis and sperm parameters in rats. *Int J Reprod Bio Med*. 2008;6(2):71-76.
12. Alan C, Koçoğlu H, Ersay A, Ertung Y, Kurt H. Unexpected severe hepatotoxicity of ciprofloxacin: two case reports. *Drug and Chemical Toxicol*. 2011; 34(2):189-191.
13. Sabeeh S, Salih R, Bdewi S, Hasan M. Effects of ciprofloxacin on liver and kidney functions and histopathological features in rats. *Int J Pharmaceutical Res*. 2019;11(1):907-911.
14. Zobeiri F, Sadrkhanlou R, Salami S, Mardani K, Ahmadi A. The effect of ciprofloxacin on sperm DNA damage, fertility potential and early embryonic development in NMRI mice. *Vet Res Forum*. 2012;3(2):131-135.
15. Abd-Allah A, Aly H, Moustafa A, Abdel-Aziz A, Hamada F. Adverse testicular effects of some quinolone members in rats. *Pharmacol Res*. 2000;41(2):211-219.
16. Folgerø T, Bertheussen K, Lindal S, Torbergsen T, Oian P. Andrology: Mitochondrial disease and reduced sperm motility. *Hum Reprod*. 1993;8(11):1863-1868.
17. Rahman MS, Kwon WS, Pang MG. Calcium influx and male fertility in the context of the sperm proteome: an update. *Bio Med Res Int*. 2014; 2014:841615.
18. Carranza-Lira S, Tserotas K, Moran C. effect of antibiotic therapy in astheno-zoospermic men associated with increased agglutination and minimal leukospermia. *Arch. Androl*. 1998;40(2):159-162.
19. Elias A, Nelson B. Sub chronic evaluation of ciprofloxacin and perfloxacin on sperm parameters of male guinea pigs. *Asian J Exp. Biol. Sci*. 2012;3(3):595-601.
20. Iqbal R, Iqbal S, Atta I. Testicular Morphological Changes Produced by Fluoroquinolones in Adult Male Albino Rats. *Annals of King Edward Medical University*. 2017;23(2):169-175
21. Weyers AI, Ugnia LI, Garcia Ovando H, Gorla NB. Ciprofloxacin increase hepatic and renal lipid hydroperoxides levels in mice. *Bio cell*. 2002;26:225-228.
22. Itoh T, Mitsumori K, Kawaguchi S, Sasaki Y. Genotoxic potential of quinolone antimicrobials in the in vitro comet assay and micronucleus test. *Mutat. Res*. 2006: 603: 135-144.
23. Sanchez G, Hidalgo ME, Vivanco JM, Escobar J. Induced and photoinduced DNA damage by quinolones: ciprofloxacin, olfoxacin and nalidixic acid determined by comet assay. *Photochem Photobiol*. 2005; 81: 819-822.
24. Shihab MA, Sadek WS. Study Genotoxicity of ciprofloxacin in white rats. *Indian J. Forensic. Med. Toxicol*. 2020;14(1):871-876.
25. Arriaga-Alba M, Sanchez R, Perez N, Navarrete J, Paz R, Montoya-Estrada A, Gomez JJH. Comparative study of the antimutagenic properties of vitamiv C and E on mutations induced by norfloxacin. *BMC Pharmacol*. 2008;8(1):1-4.
26. Taslidere E, Dogan Z, Elbe H, Vardi N, Cetin A, Turkon Y. Quercetin protection against ciprofloxacin induced liver damage in rats. *Biotechnic. Histochem*. 2016; 91(2): 116-121.
27. Channa MA, Janjua MZJ. Effects of ciprofloxacin on foetal hepatocytes. *Pak. Med. Assoc*. 2003; 53: 448-450
28. Nashwa AA, Kawkab AA, Mouneir SM. The protective effect of ginger and N-acetyl cysteine on ciprofloxacin-induced reproductive toxicity in male rats. *J. Am. Sci*. 2011; 7(7):741-752.
29. Friedman JM, Polifka JE. *Teratogenic effects drugs: a resource for clinicians (TERIS)*. Baltimore: Johns Hopkins University. 2000; 149-195.
30. Nahum GG, Uhl K, Kennedy D. Antibiotic use in pregnancy and lactation: what is and is not known about teratogenic and toxic risks. *Obstet. Gynecol*. 2006; 107: 1120-1138.

31. Siddiqui A, Nagui S. Evaluation of teratogenic potentials of ciprofloxacin in albino rats. J Morphol Sci. 2010;27(1):14-18.
32. Jeffery W, Soo K, James D, Lisa A, Nicholas A, Lee T, Sharon R. Inhibition of clinically relevant mutant variants of HIV by quinazolinone non-nucleoside reverse transcriptase inhibitors. J. Med Chem. 2000; 43(10): 2019-2030.
33. Arriaga-Alba M, Rivera-Sanchez R, Parra Cervantes G, Barro-Moreno F, Flores-Paz R, Garcia-Jimenez E. Antimutagenesis of b-carotene to mutations induced by quinolone on Salmonella typhimurium. Arch Med Res. 2000; 31(2):156-161.

## السيبروفلوكساسين يؤثر على جودة الحيوانات المنوية ويسبب ضرر للخصية والكبد في ذكور الفئران

سميرة ساسي<sup>1\*</sup>، ناجية الغول<sup>2</sup>، سمية التومي<sup>1</sup>، نوري عوين<sup>3</sup>، وليد السعداوي<sup>4</sup>، راجيل براستيا<sup>5</sup>

<sup>1</sup>قسم علم الحيوان، كلية العلوم، جامعة طرابلس، طرابلس، ليبيا  
<sup>2</sup>مركز بحوث التقنيات الحيوية، طرابلس، ليبيا  
<sup>3</sup>قسم الكيمياء، كلية العلوم، جامعة طرابلس، طرابلس، ليبيا<sup>4</sup>  
<sup>4</sup>المركز الوطني لمكافحة الأمراض، وزارة الصحة، طرابلس، ليبيا  
<sup>5</sup>قسم الانجاب، كلية الصحة وعلوم الحياة، جامعة إيرلانجا، سورابايا، إندونيسيا

### المستخلص

سيبروفلوكساسين هو أحد المضادات الحيوية من الجيل الثاني من مجموعة الفلوروكينولون، يوصف كثيرا لعلاج العدوى البكتيرية. كان الهدف من هذه الدراسة هو تقييم تأثير مضاد السيبروفلوكساسين على خصائص النطف، DNA الكبد والبنية النسيجية للكبد والخصي. تم تقسيم أربعة وعشرين فأرا ذكرا تتراوح أعمارهم بين 7 و 10 أسابيع إلى ثلاثة مجموعات (ثمانية في كل مجموعة). أعطيت المجموعة الأولى (الضابطة) ماء مقطر. المجموعة الثانية والثالثة أعطيت سيبروفلوكساسين بجرعات 500 و 750 ملجم/كجم على التوالي. تم إعطاء الجرعات عن طريق الفم ولمدة 14 يوما. تم وضع ثلاثة إناث غير معاملة مع ذكر معاملة بالمضاد للتزاوج. عند نهاية فترة التجريب، تم قتل الفئران وإزالة الخصي والكبد ووزنها. تم قياس معايير النطف، مستوى هرمون التستوستيرون و DNA الكبد. بعد ذلك، تم إجراء الفحص النسيجي للكبد والخصي. أظهرت النتائج أن سيبروفلوكساسين أثر بشكل كبير على DNA الكبد، حركة النطف وشكلها بالإضافة إلى أنه تسبب في حدوث تغيرات نسيجية مرضية في أنسجة الكبد والخصي. علاوة على ذلك، أدى إلى ارتفاع معنوي في نسبة الأجنة الميتة وكذلك الأجنة المشوهة. تشير النتائج إلى أن سيبروفلوكساسين له تأثيرات ضارة على جودة النطف، DNA الكبد والبنية النسيجية للخصي والكبد؛ لذلك، يجب استخدامه بحذر شديد.

**الكلمات المفتاحية:** سيبروفلوكساسين، الخصي، الكبد، الفئران، الأجنة.