

Original article

# Radioprotective Effects of Folic Acid on Hematological Parameters and Bone Marrow Histology in Male Rabbits Exposed to X-Ray Irradiation

Haiba Essam<sup>1</sup>, Muneerah Abdulsayid<sup>2</sup>, Munay Alsunosi<sup>3</sup>, Amal Srgewa<sup>\*2</sup>

<sup>1</sup>Department of Histology, Faculty of Medicine, University of Derna, Derna, Libya

<sup>2</sup>Department of Pathology, Faculty of Medicine, University of Derna, Derna, Libya

<sup>3</sup>Department of Physiology, International Academic University, Derna, Libya

Corresponding Email. [A.srgewa@uod.edu.ly](mailto:A.srgewa@uod.edu.ly)

## Abstract

Ionizing radiation is known to induce significant damage to the hematopoietic system, primarily compromising bone marrow function. Folic acid plays a crucial role as a cofactor in one-carbon metabolism and various cellular processes, including DNA synthesis and repair. This study examines the potential radioprotective effects of folic acid on hematological parameters and bone marrow histology in male rabbits subjected to X-ray irradiation. The experimental design included four groups: (1) Control, (2) Folic acid supplementation, (3) X-ray exposure, and (4) Combined folic acid supplementation and X-ray exposure. Hematological analysis demonstrated a significant decline in white blood cell (WBC), red blood cell (RBC), and platelet (PLT) counts following X-ray exposure, indicating radiation-induced hematopoietic suppression. Notably, folic acid supplementation partially restored these parameters, suggesting its role in promoting hematopoietic recovery. Additionally, histological examination of bone marrow revealed increased cellularity in folic acid-treated groups, further supporting its protective effects against radiation-induced myelosuppression. These findings indicate that folic acid supplementation may attenuate the adverse hematopoietic effects of ionizing radiation, underscoring its potential as a radioprotective agent.

**Keywords.** Radioprotective, Folic Acid, Hematological, Bone Marrow, Histopathology.

## Introduction

Radiation-induced damage to the hematopoietic system is a well-documented consequence of ionizing radiation exposure, primarily affecting bone marrow function and peripheral blood cell counts. Ionizing radiation generates reactive oxygen species (ROS), leading to oxidative stress and cellular apoptosis, particularly in hematopoietic stem and progenitor cells [1,2]. Folic acid, an essential B vitamin involved in DNA synthesis and repair, has been hypothesized to possess radioprotective properties.

Acute Radiation Syndrome (ARS), commonly referred to as radiation sickness, occurs as a result of whole-body exposure to high doses of ionizing radiation. This condition is characterized by significant disruptions in biochemical parameters and can adversely impact multiple organ systems, including the hematopoietic [3], cardiovascular [4], and gastrointestinal systems [5]. Furthermore, developing brains are particularly vulnerable to ionizing radiation, as evidenced by numerous studies [6]. Prenatal exposure to X-irradiation has been associated with histological changes in the brain of both humans and experimental animals, leading to impairments in learning and memory [7].

Hematopoietic stem cells, known for their high radiosensitivity, play a crucial role in maintaining blood cell counts, which remain a critical diagnostic tool in assessing disease conditions. Prolonged exposure to X-rays has been shown to cause significant alterations in peripheral blood cell profiles, including an increase in neutrophil count, severe lymphopenia, and thrombocytopenia due to a reduction in platelet levels. Ionizing radiation typically suppresses bone marrow activity, leading to decreased production of blood cells in peripheral circulation, although its direct effects on most cells or tissues are relatively rare [8]. The systemic effects of whole-body radiation primarily manifest in the hematological, gastrointestinal, and cerebrovascular systems, resulting in widespread dysfunction and organ damage [9,10]. These insights underscore the broad and complex biological impact of ionizing radiation on both cellular and systemic levels.

Hematopoietic stem cells, being highly radiosensitive, play a vital role in monitoring disease conditions, with platelet counts serving as a reliable diagnostic indicator. Exposure to ionizing radiation doses ranging from 0.5 to 1 Gy can result in significant changes in peripheral blood cell profiles, including elevated neutrophil counts, severe lymphopenia, and reduced platelet levels (thrombocytopenia). Lymphocytes are particularly susceptible to radiation-induced damage, undergoing interphase death even at low doses of 0.05–0.15 Gy. Ionizing radiation suppresses bone marrow activity, leading to a reduction in peripheral blood cell production, although it inflicts minimal direct harm on most cells or tissues [8]. The systemic effects of radiation extend to various organ systems, including the gastrointestinal, cerebral, and circulatory systems, resulting in widespread organ dysfunction [9,10]. Radiation-induced bone marrow suppression and decreased peripheral blood counts highlight the importance of hematopoiesis recovery in treating radiation injuries [11].

Research by Li and colleagues (2014) [12] suggests that radiation not only diminishes hematopoietic cell numbers but also stimulates the activation of remaining cells. In a study by Geng et al. [8], mice exposed to

$^{60}\text{Co}$   $\gamma$ -rays exhibited a decline in red blood cell (RBC) count, hemoglobin (Hb) concentration, white blood cell (WBC) count, and lymphocyte percentage. Notably, WBCs and lymphocytes demonstrated greater radiosensitivity than RBCs and Hb, likely due to the longer lifespans of mature RBCs and Hb compared to WBCs. In 2005, Deng et al. [13] also reported a pronounced reduction in WBCs following radiation exposure. Since lymphocytes retain immature potential even after differentiation, the initial observable effect of ionizing radiation on blood cells is a sharp decline in lymphocyte counts. Previous studies examining radiation's impact on leukocytes consistently highlight the early and profound susceptibility of lymphocytes to radiation-induced damage.

Folic acid functions as a cofactor in single-carbon metabolism and various cellular processes, such as the biosynthesis of purines, thymidylate, and methionine [14]. It serves as a unique body coenzyme with antioxidant properties that support erythropoiesis, DNA synthesis [15], amino acid metabolism within DNA [16], sperm production [17], and overall male fertility [18].

Additionally, specific medications, such as antacids, triamterene, anticonvulsants, cimetidine, anticancer drugs, and sulfasalazine, can interfere with folic acid levels in the body. Pregnant women or those planning pregnancy are advised to consume 400 micrograms of folic acid daily to reduce the risk of neural tube defects and other pregnancy complications. In some cases, physicians may also recommend this dosage to decrease the risk of cardiovascular diseases [18].

The Food and Drug Administration (FDA) mandates the fortification of cereals with folic acid, allowing individuals who regularly consume fortified grains to meet their daily folic acid requirement with as little as 100 micrograms. However, research by Tolba et al. [16] indicates that this minimal intake is often insufficient to maintain optimal folic acid levels in the body, underscoring the importance of ensuring adequate dietary supplementation. This study aims to assess the protective effects of folic acid supplementation in mitigating hematological and histological damage to bone marrow in rabbits exposed to X-ray irradiation.

## Methods

### **Experimental animals**

The study utilized 20 native adult male rabbits, with body weights ranging from 2.00 to 2.32 kilograms. The animals were housed in group cages measuring 100 × 85 × 45 cm at the Zoology Department facilities at Omar Al-Mukhtar University. Environmental conditions were maintained at a temperature of 25 ± 1°C, with a photoperiod of 12 hours of light and 12 hours of darkness. The rabbits were provided with unrestricted access to water and fed a standard commercial pellet diet. To ensure proper acclimatization, the animals were housed under laboratory conditions for one week prior to the initiation of the experiment.

### **Experimental groups and protocol**

The rabbits were randomly assigned to one of four experimental groups, with five rabbits in each group: Group I (control group): Normal, healthy rabbits receiving distilled water orally each day. Group II (folic acid supplemented group): Healthy male rabbits administered folic acid at a dose of 0.07 mg/kg of body weight daily for one month [17]. Group III (X-Ray exposed group): Healthy male rabbits exposed to X-ray irradiation at a dose of 80 kV from a distance of 98 cm, once daily for one week [18]. Group IV (Combined Treated with folic acid and exposed to x ray group): Healthy male rabbits treated with folic acid at 0.07 mg/kg of body weight daily for one month, followed by X-ray irradiation at a dose of 80 kV from a distance of 98 cm, once daily for one week. All experimental procedures were conducted over a period of one month.

### **Morphological and Clinical Observations**

Daily observations were conducted to record behavioral changes and external clinical signs, including dehydration, changes in eye colour, body hair condition, stool consistency, respiratory difficulties, signs of bone fragility, fever, muscle weakness, alterations in activity levels, signs of toxicity, or mortality.

The body weights of all rabbits were measured at the beginning and end of the experimental period using an electronic balance. Body weight changes (as a percentage) and weight gain were calculated to assess the [19]. These observations were critical for evaluating the physiological and morphological responses of the animals to the treatments administered.

### **Haematological parameters**

Hematological parameters, including white blood cell (WBC) count, red blood cell (RBC) count, hematocrit (HCT), hemoglobin (HGB) levels, and platelet (PLT) count, were analyzed using an automated hematology analyzer (XP-300 Automated Hematology Analyzer, Sysmex America, Inc.).

### **Histopathological studies**

At the conclusion of the experiment, animals were euthanized by cervical dislocation, followed by postmortem examinations to detect any abnormalities or notable alterations in internal organs. Skin, liver, testis, and bone marrow samples were carefully excised for further analysis.

The tissues were fixed in 10% formalin solution for 24 hours, dehydrated using a graded series of ethyl alcohol, and cleared with xylene. Samples were embedded in paraffin wax with a melting point of 56–60°C

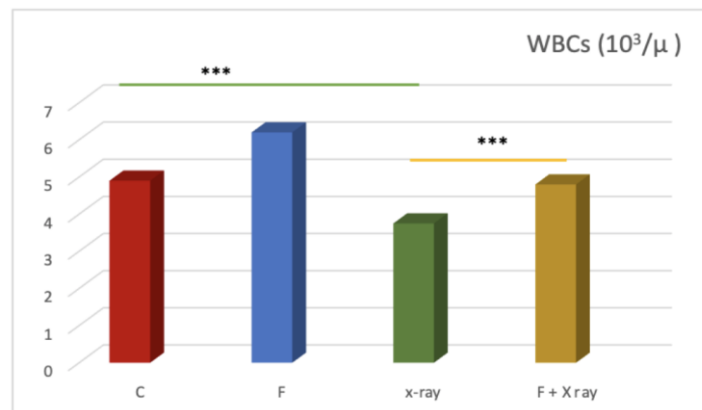
after undergoing three cycles of paraffin infiltration. Paraffin blocks were sectioned into 5–7  $\mu\text{m}$  thick slices using a Leica RM 2125 rotary microtome. Sections were stained with Harris's hematoxylin and eosin (H&E) following the protocol outlined by [20]. Slides were mounted using Canada balsam and covered with a coverslip. A light microscope equipped with a digital camera (Nikon Eclipse E400) was used to evaluate and document histological changes.

### Statistical analysis

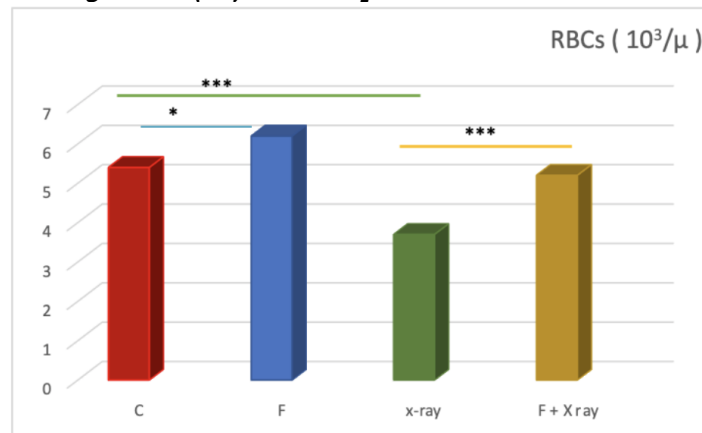
Statistical analyses were performed using SPSS (version 27). A one-way analysis of variance (ANOVA) followed by Tukey's Honest Significant Difference (HSD) test was employed to evaluate differences between group means. Results were expressed as mean  $\pm$  standard error of the mean (SEM), with statistical significance defined as a P-value  $< 0.05$ . On the graph if a p-value is less than 0.05, it is flagged with one star (\*). If a p-value is less than 0.01, it is flagged with 2 stars (\*\*). If a p-value is less than 0.001, it is flagged with three stars (\*\*\*)

### Results

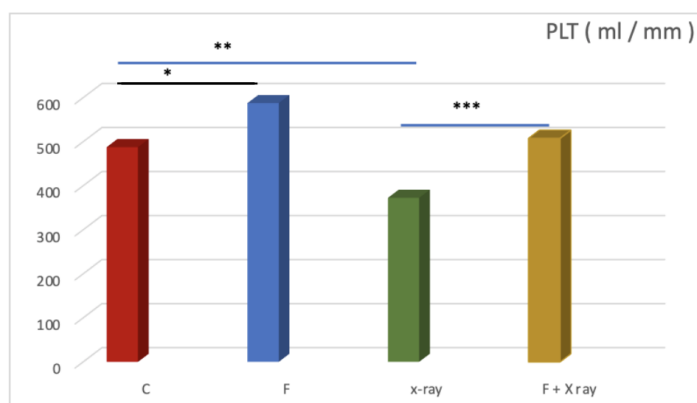
Effect of folic acid supplementation and X-ray exposure on CBP parameters in male rabbits exposed to X rays.



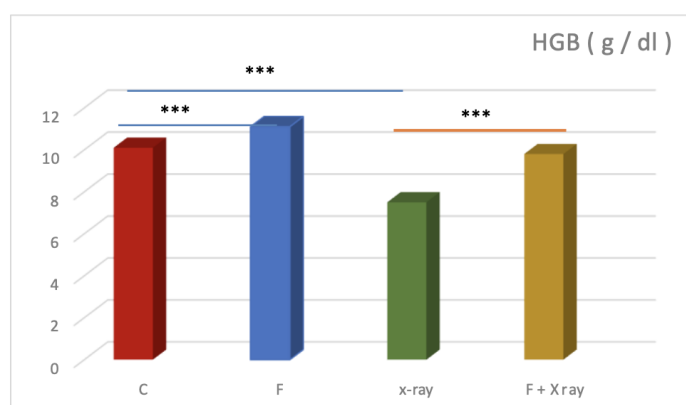
**Figure 1. WBC count of the studied groups. Folic acid administered group has the highest WBC count, suggesting a strong response (possibly an immune reaction or inflammation). X-ray exposure seems to decrease WBC count, which may indicate radiation-induced suppression of white blood cells. The combination of FA and X-ray shows an intermediate effect, reducing WBC count but not as drastically as X-ray alone. (\*\*\*) indicate p-value less than 0.001.**



**Figure 2. RBCs count of the studied group. Folic acid group (F) increases RBC count significantly, suggesting a stimulatory effect (possibly an erythropoietic response)., X-ray exposure seems to reduces RBC count, likely due to radiation-induced bone marrow suppression, The combination of FA and X-ray shows partial recovery, meaning F might counteract some of the suppressive effects of X-ray on RBC production. (\*) indicate p-value less than 0.05; (\*\*\*) indicate p-value less than 0.001.**



**Figure 3. Platelets count of the studied groups. Folic acid group (F) shows an increase platelet count, suggesting a stimulatory effect (possibly enhancing megakaryocyte activity or bone marrow function), X-ray exposure seems to reduce platelet count, likely due to radiation-induced suppression of bone marrow. The combination of FA and X-ray shows partial recovery, meaning F might counteract some of the suppressive effects of X-ray on platelet production. (\*) indicate p-value less than 0.05; (\*\*) indicate p-value less than 0.01; (\*\*\*) indicate p-value less than 0.001.**



**Figure 4. HGB level of the studied groups. The group which was given folic acid has the highest HGB level, and, X-ray exposure seems to decrease haemoglobin, which may indicate radiation-induced suppression of HGB, the combination of FA and X-ray shows an intermediate effect, reducing HGB level but not as drastically as X-ray alone. (\*\*\*) indicate p-value less than 0.001.**

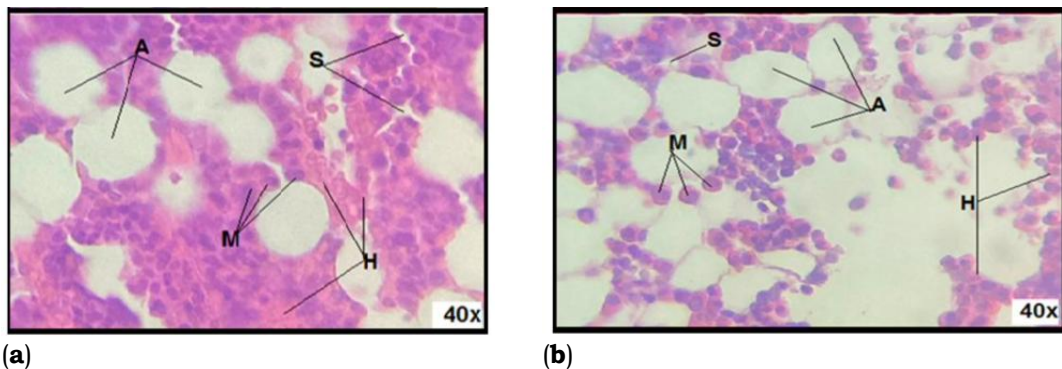
The significant drop in the X-ray-exposed group suggests radiation-induced anemia, likely caused by damage to hematopoietic stem cells in the bone marrow, leading to impaired erythropoiesis. Folic acid appears to mitigate the harmful effects of radiation by supporting red blood cell production and maintaining hemoglobin levels, aligning with its known role in DNA synthesis and erythropoiesis. The group which was given folic acid and exposed to X-ray group, while showing improvement compared to X-ray alone, does not reach the levels of the control or folic acid-only groups, suggesting that radiation damage still has a lasting effect despite folic acid supplementation.

#### **The possible Radio-protector effect of folic acid on BM histological structure in male rabbits exposed to X ray**

Figure 5 (a) illustrates the section of the Control Group which shows a normal bone marrow architecture with a balanced ratio of hematopoietic cells (H) and adipocytes (A), while the presence of megakaryocytes (M) and stromal cells (S) suggests normal platelet production and bone marrow support. Figure 5 (b) indicates the bone marrow section of the rabbits group which was administered folic acid, showing an increased hematopoietic activity, with a higher density of hematopoietic cells (H). More megakaryocytes (M), suggesting enhanced platelet formation. Slightly reduced adipocyte (A) content, indicating a shift towards active blood cell production.

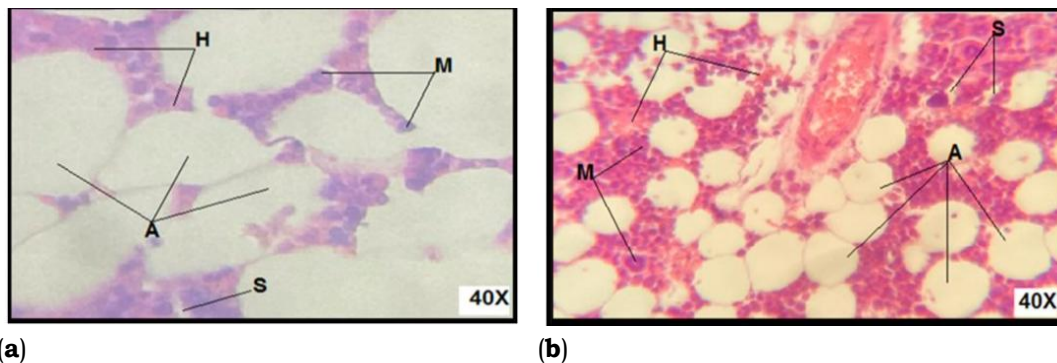
That indicates that folic acid administration enhances hematopoiesis, increasing blood cell production and supporting bone marrow function. The control group shows normal bone marrow architecture, whereas folic acid appears to stimulate hematopoietic cell proliferation, which aligns with folic acid's role in DNA synthesis and cell division, benefiting overall bone marrow health.





**Figure 5. 40x (H.E), Photomicrograph illustrates bone marrow sections of rabbits, showing hemopoietic cells admixed with adipocytes; H= Hematopoietic cells, A= Adipocytes, M= Megakaryocytes, S= Sinusoids: (a) Control group; (b) after folic acid administration: normal hemopoietic population.**

The section of bone marrow of group which exposed to X-ray (figure 6a) shows Increased fat cells (A) and reduced hematopoietic cells (H) indicate radiation-induced bone marrow suppression; The structure seems more damaged, showing lower cellularity and signs of atrophy. On other hand, combined administration during x-ray exposure (figure 6 b); suggests partial protection against radiation damage indicated by the presence of hematopoietic cells (H), megakaryocytes (M), and adipocytes (A); The marrow appears more cellular, with better-preserved components.



**Figure 6. 40x (H.E), Photomicrograph illustrates bone marrow sections of rabbits, showing hemopoietic cells admixed with adipocytes; H= Hematopoietic cells, A= Adipocytes, M= Megakaryocytes, S= Sinusoids: (a) exposed to X-ray showing depletion of hematopoietic cells; (b) after folic acid administration: exposed to X-ray and folic acid group: improvement in hemopoietic population.**

## Discussion

The present study objective was to evaluate the potential beneficial effects of folic acid as radioprotective on hematological parameters and bone marrow histological structures in male rabbits exposed to X-ray radiation. The results demonstrated that X-ray exposure significantly reduced WBC, RBC, and platelet counts, while folic acid supplementation partially mitigated these effects. Histological analysis further revealed that X-ray exposure led to depletion of hematopoietic cells, whereas folic acid treatment contributed to cellular recovery. These findings align with prior research, emphasizing the detrimental effects of ionizing radiation on hematopoiesis and the potential protective role of folic acid. Similarly, mice exposed to 8 Gy or 15 Gy doses of irradiation showed no mortality or significant neurological deficits within 24 hours post-irradiation [21].

Radiation-induced hematopoietic suppression has been extensively documented in previous studies. Ionizing radiation affects bone marrow function by increasing oxidative stress, leading to DNA damage and apoptosis of hematopoietic stem cells [12]. The observed reduction in RBC, WBC, and platelet counts in the X-ray-exposed rabbits is consistent with findings reported by Coleman et al. [9] and Xiao & Whitnall [10], who noted that radiation disrupts multiple organ systems, particularly hematopoietic and immune functions. Similarly, a study [22] linked radiation exposure to declines in hemoglobin and erythrocyte counts, attributing these changes to oxidative stress and bone marrow suppression.

In the current study, histological analysis revealed a depletion of hematopoietic cells and an increase in adipocytes in X-ray-exposed rabbits, indicative of bone marrow atrophy. These findings correspond with prior reports highlighting radiation-induced hypoplasia in the hematopoietic system [23,24]. Notably, Fuks and his colleagues [25] and Matsumoto and his team [26] documented similar effects, showing that radiation exposure leads to significant alterations in peripheral blood composition and lymphoid organ weight.

The administration of folic acid before X-ray exposure resulted in a partial recovery of hematological parameters and bone marrow cellularity. This protective effect is likely due to folic acid's essential role in DNA synthesis and repair, as well as its function in reducing oxidative stress [27]. Previous studies have

demonstrated that folic acid supplementation enhances hematopoiesis and mitigates radiation-induced damage by reducing reactive oxygen species (ROS) and improving cellular proliferation [28,12]. Moreover, the observed increase in WBC, RBC, and platelet counts in the folic acid-treated group aligns with findings by Gridley et al. [24], who reported that dietary supplementation with folate and other antioxidants enhances hematopoietic recovery following radiation exposure. These effects are likely mediated through folic acid's role in methylation and nucleotide biosynthesis, which are crucial for maintaining genomic integrity under stress conditions [29]. The decrease in hematological parameters observed in X-ray-exposed rabbits is consistent with earlier studies [9,10], which reported that whole-body irradiation disrupts various organ systems, including hematological, gastrointestinal, and cerebrovascular systems. Ionizing radiation has been shown to cause bone marrow destruction and peripheral blood cell depletion. Li et al. [12] further demonstrated that radiation exposure increases reactive oxygen species (ROS) in hematopoietic stem cells, bone marrow, hematopoietic progenitor cells, and mononuclear cells, leading to cellular damage. Singh and Roy [22] attributed reductions in hemoglobin and RBC counts to radiation toxicity, while leucocyte decline was linked to inflammatory responses.

Numerous studies have corroborated the impact of radiation on bone marrow [23], peripheral blood [25,26], lymphoid organ weight [22], and other biological tissues, with the extent of damage varying according to the radiation dose received. Anemia, a common side effect of radiation therapy and chemotherapy, is attributed to decreased erythrocyte counts following radiation exposure [24]. The current study's findings corroborate those of previous investigations into the radioprotective properties of dietary supplements. For example, Coleman et al. [9] reported that folic acid and other antioxidants protect against radiation-induced damage by scavenging free radicals and promoting DNA repair mechanisms. Similarly, a study by Scott & Lyons in 1979 [30] found that folic acid administration improved erythropoiesis and immune function in irradiated subjects. The beneficial effects observed in the present study further support the hypothesis that folic acid acts as a radioprotective agent, reducing hematopoietic suppression and promoting recovery. Additionally, research [26] demonstrated that folic acid supplementation enhances hematopoietic stem cell survival following radiation exposure by modulating oxidative stress responses. These findings align with the present study's histological observations, where folic acid-treated rabbits exhibited improved cellular architecture, with a well-preserved hematopoietic population and reduced adipocyte infiltration compared to the X-ray-exposed group. These findings align with earlier researches [9,10], which reported that whole-body radiation causes dysfunction in multiple organ systems, including the hematopoietic, gastrointestinal, and cerebrovascular systems. Ionizing radiation exposure has been shown to damage bone marrow, resulting in reduced peripheral blood cell counts [12]. Additionally, radiation-induced oxidative stress, characterized by increased reactive oxygen species (ROS) in hematopoietic stem cells and other bone marrow cells, contributes to this dysfunction. Singh and Roy [22] attributed declines in hemoglobin and RBC counts to toxic effects, while inflammation, acting as a defensive mechanism, accounted for the reduction in leukocytes.

### **Limitations and future directions**

While this study provides strong evidence supporting the radioprotective effects of folic acid, several limitations should be acknowledged. First, the study was conducted on a small sample size of male rabbits, and further investigations with larger cohorts and different animal models are warranted. Second, molecular mechanisms underlying folic acid's protective effects, particularly its role in DNA repair pathways and antioxidant enzyme modulation, require further exploration. Future research should focus on the long-term effects of folic acid supplementation post-radiation exposure and its potential applications in clinical settings.

### **Conclusion**

The findings of this study indicate that folic acid supplementation plays a significant role in reducing the damaging effects of X-ray exposure on blood parameters and bone marrow histology. The observed improvements in WBC, RBC, platelet and hemoglobin counts, along with stimulating haematopoiesis, suggest that folic acid has radioprotective properties. These results align with previous research, emphasizing the potential therapeutic applications of folic acid in radiation-exposed populations. Hematological Analysis indicate that folic acid administration exhibited the highest WBC, RBC, and PLT counts and HGB level, while X-ray exposure resulted in a significant reduction, indicative of radiation-induced bone marrow suppression. However, the treatment with folic acid with X-ray exposure showed partial recovery, implying a potential protective effect of folic acid against radiation damage. Histological analysis shows the effect of X-ray exposure on BM tissue which shown as severe depletion of hematopoietic cells, increased adipocyte content, and disrupted bone marrow architecture. However, moderate recovery of hematopoietic cellularity, reduced adipocyte infiltration, and enhanced megakaryocyte presence

### **Acknowledgments**

We acknowledge the support given from faculty of science, Omar-Almukhtar University; Faculty of Medicine, university of Derna.

## Conflicts of Interest

The authors declare no conflicts of interest.

## References

- Bhosle SM, Huilgol NG, Mishra KP. Enhancement of radiation-induced oxidative stress and cytotoxicity in tumor cells by ellagic acid. *Clin Chim Acta*. 2005;359:89–100.
- Zhang Y, Chen X, Wang X, Chen J, Du C, Wang J, Liao W. Insights into ionizing radiation-induced bone marrow hematopoietic stem cell injury. *Stem Cell Research & Therapy*. 2024 Jul 23;15(1):222.
- Freitas RB, Augusti PR, Andrade RA, Rother FC, Rovani BT, Quatrin A, et al. Black grape juice protects spleen from lipid oxidation induced by gamma radiation in rats. *J Food Biochem*. 2014;38(1):119–127.
- Mansour HH, Tawfik SS. Early treatment of radiation-induced heart damage in rats by caffeic acid phenethyl ester. *Eur J Pharmacol*. 2011;692:46–51.
- Messarah M, Saoudi M, Boumendjel A, Boulakoud MS, Feki AE. Oxidative stress induced by thyroid dysfunction in rat erythrocytes and heart. *Environ Toxicol Pharmacol*. 2011;31:33–41.
- Miki T, Fukui Y, Takeuchi Y, Itoh M. A quantitative study of the effects of prenatal X-irradiation on the development of cerebral cortex in rats. *Neurosci Res*. 1995;23(3):241–247.
- Miki T, Sawada K, Sun XZ, Hisano S, Takeuchi Y, Fukui Y. Abnormal distribution of hippocampal mossy fibers in rats exposed to X-irradiation in utero. *Brain Res Dev Brain Res*. 1999;112(2):275–280.
- Geng Y, Xiaogang DX, Cao X, Chen Y, Zhang H, Liu H, et al. The therapeutic effects of Zingiber officinale extract on mice irradiated by <sup>60</sup>Co  $\gamma$ -ray. *J Med Plants Res*. 2012;6(13):2590–2600. Available from: <http://www.academicjournals.org/JMPR>.
- Coleman CN, Stone HB, Moulder JE, Pellmar TC. Modulation of radiation-induced damage to normal tissues by biological response modifiers.
- Xiao M, Whitnall MH. Pharmacological countermeasures for the acute radiation syndrome. *Curr Mol Pharmacol*. 2009;2(2):122–133.
- Li D, Lu L, Zhang J, Wang X, Xing Y, Wu H, et al. Mitigating the effects of Xuebijing injection on hematopoietic cell injury induced by total body irradiation with  $\gamma$  rays by decreasing reactive oxygen species levels. *Int J Mol Sci*. 2014;15:10541–10553.
- Tak JK, Park JW. The use of ebselen for radioprotection in cultured cells and mice. *Free Radic Biol Med*. 2009;46(8):1177–1185.
- Deng QC, Chen CY, Duan HK, Wang L, Xie BJ. Protection effect of ginkgo albumin extract on  $\gamma$ -ray irradiated mice. *J Radiat Res Radiat Process*. 2005;23(6):359–365.
- Panche AN, Diwan AD, Chandra SR. Flavonoids: An overview. *J Nutr Sci*. 2016;5:e47. PMC8649804.
- Stanger O. Physiological role of vitamins in erythropoiesis and DNA synthesis. Springer; 2002.
- Tolba A. The role of coenzymes in amino acid metabolism and DNA function. *J Biochem Res*. 2015;12(3):214–228.
- Kamen B. Coenzyme Q10 and its role in male reproductive health. *Fertil Steril*. 1997;68(4):678–685.
- Feng Y, Wang S, Chen R, Tong X, Wu Z. Maternal folic acid supplementation and the risk of congenital heart defects in offspring: A meta-analysis of epidemiological observational studies. *Sci Rep*. 2015;5:8506.
- Tülüncü M, Ozbek H, Bayram I, Cengiz N, Ozgokce F, Him A. The effects of diethylether extract of *Helichrysum plicatum* DC. Subsp. *plicatum* and *Tanacetum balsamita* L. subsp. *balsamitoides* (Sch. Bip.) Grierson (Asteraceae) on the acute liver toxicity in rats. *Asian J Anim Vet Adv*. 2010;5(7):465–471.
- Bancroft JD, Gamble M. Theory and practice of histological techniques. 6th ed. Churchill Livingstone; 2008.
- Guney Y, Bilgihan A, Hicsonmez A, Dizman A, Andrieu M, Kurtman C. Influence of different doses of irradiation on oxidant and antioxidant systems in the brain of guinea pigs. *American Journal of Immunology*. 2005;1(3):114–8.
- Singh VK, Roy A. Radioprotective potential of dietary antioxidants: A review. *Indian J Exp Biol*. 2014;52(6):489–500.
- Till JE, McCulloch EA. A direct measurement of the radiation sensitivity of normal mouse bone marrow cells. *Radiat Res*. 1961;14(2):213–222.
- Gridley DS, Pecaut MJ, Nelson GA. Total-body irradiation with high-LET particles: Acute and chronic effects on the immune system. *Am J Physiol Regul Integr Comp Physiol*. 2002;282(6):R1774–R1787.
- Fuks Z, Seddon AP, Elkind MM. Mechanisms of hematopoietic suppression by ionizing radiation. *Radiat Res*. 1976;67(3):536–550.
- Matsumoto H, Takahashi T, Seki M. Effects of ionizing radiation on bone marrow cells: Mechanisms of apoptosis induction. *Radiat Res*. 1998;149(4):413–421.
- Lucock M. Folic acid: Nutritional biochemistry, molecular biology, and role in disease processes. *Mol Genet Metab*. 2000;71(1-2):121–138.
- Bailey LB, Gregory JF. Folate metabolism and requirements. *J Nutr*. 1999;129(4):779–782.
- Blount BC, Mack MM, Wehr CM, MacGregor JT, Hiatt RA, Wang G, et al. Folate deficiency causes uracil misincorporation into human DNA and chromosome breakage: Implications for cancer and neuronal damage. *Proc Natl Acad Sci U S A*. 1997;94(7):3290–3295.
- Scott BR, Lyons TJ. Effect of folic acid on hematopoietic recovery following radiation exposure. *Int J Radiat Biol*. 1979;36(1):81–88.

### المستخلص

تُعرف الأشعة المؤينة بتسببها في أضرار كبيرة للجهاز المكون للدم، مما يؤدي بشكل أساسي إلى ضعف وظيفة نخاع العظم. حمض الفوليك يلعب دورًا حيويًا كعامل مساعد في عمليات التمثيل الأحادي للكربون والعديد من العمليات الخلوية، بما في ذلك تخليق وإصلاح الحمض النووي. تهدف هذه الدراسة إلى فحص التأثيرات الإشعاعية الوقائية المحتملة لحمض الفوليك على المعايير الدموية وتاريخ نخاع العظم المرضي في ذكور الأرانب المعرضة للأشعة السينية. شمل التصميم التجريبي أربع مجموعات: (1) مجموعة التحكم، (2) مجموعة مكملات حمض الفوليك، (3) مجموعة التعرض للأشعة السينية، و(4) مجموعة الجمع بين مكملات حمض الفوليك والتعرض للأشعة السينية. أظهر التحليل الدموي انخفاضًا ملحوظًا في تعداد كريات الدم البيضاء وكريات الدم الحمراء والصفائح الدموية بعد التعرض للأشعة السينية، مما يشير إلى كبت تكون الدم الناجم عن الإشعاع. ومن الجدير بالذكر أن مكملات حمض الفوليك أدت إلى استعادة جزئية لهذه المعايير، مما يشير إلى دوره في تعزيز التعافي الدموي. بالإضافة إلى ذلك، كشف الفحص النسيجي لنخاع العظم عن زيادة في كثافة الخلايا في المجموعات المعالجة بحمض الفوليك، مما يدعم تأثيره الوقائي ضد كبت النخاع الناجم عن الإشعاع. تشير هذه النتائج إلى أن مكملات حمض الفوليك قد تخفف من التأثيرات الدموية الضارة للإشعاع المؤين، مما يبرز إمكانيته كعامل وقائي إشعاعي.