

Original study

The Importance of Early Treatment of Frontal Fibrosing Alopecia

Fauzia Musbah¹, Saja Lagha^{1*} , Mohmed Tabib²

¹Department of Dermatology, Tripoli Central Hospital, Tripoli, Libya.

²Department of Internal Medicine, Tripoli Central Hospital, Tripoli, Libya.

ARTICLE INFO

Corresponding Email. Laghasaja@gmail.com

Received: 30-08-2024

Accepted: 23-10-2024

Published: 02-11-2024

Keywords. Frontal Fibrosing Alopecia, Scarring Alopecia, Trichoscopy, Retrospective Study.

Copyright: © 2024 by the authors. Submitted for possible open access publication under the terms and conditions of the Creative Commons Attribution International License (CC BY 4.0).

<http://creativecommons.org/licenses/by/4.0/>

ABSTRACT

Frontal fibrosing alopecia (FFA) a variant of lichen planopilaris (LPP) described a gradual recession affecting the frontoparietal region in postmenopausal women, with the stark difference between the pale, smooth skin and the sun-damaged skin on the forehead, By trichoscopy, there's a lack of hair follicle openings and the presence of perifollicular erythema at the hairline. With histopathological features include lymphocytic infiltration and fibrosing of the root sheet of hair follicle. We aimed to determine the relation between the duration of the disease and response to early initiation of different treatments. We conducted a retrospective study, including 16 cases of FFA from Tripoli Central Hospital, spanning from November 2019 to November 2023. In this study, we used data extracted from patients' follow-up records, which included information on demographics, disease history, examination results, trichoscopy findings, and administered treatments. The process of data entry and analysis was conducted using SPSS 26. We found out of 16 participants which were all females, mean age of 53.50 (± 4.94), history of duration in months was 54 (42-62). There was a statistically significant negative strong association between the response to the treatment and the duration of the disease, $\tau b = -0.574$, $p\text{-value} = 0.011$.

Cite this article. Musbah F, Lagha S, Tabib M. The Importance of Early Treatment of Frontal Fibrosing Alopecia. *Alq J Med App Sci.* 2024;7(4):1121-1125. <https://doi.org/10.54361/ajmas.247429>

INTRODUCTION

In 1994, Kossarden initially described frontal fibrosing alopecia (FFA) a variant of lichen planopilaris (LPP) as a gradual recession affecting the frontoparietal region in postmenopausal women, emphasizing the stark difference between the pale, smooth skin and the sun-damaged skin on the forehead, upon inspection, it was noted that there was a lack of hair follicle openings and the presence of perifollicular erythema at the hairline, histopathological features include lymphocytic infiltration and fibrosing of the root sheet of the hair follicles which are similar to LPP, Pseudopelade of brocq, and lupus erythematosus, regardless of the hair cycle phase, the inflammatory infiltrates affect all types of hair (terminal, intermediate, and vellus) concurrently, individuals may also experience alopecia of the eyebrows, axilla, and pubic region, these areas, along with the limbs, are commonly accompanied by itching and burning sensation [1, 2].

To date, three distinct patterns have been identified thus far: linear (type I), zigzag or diffuse (type II), and pseudo fringe (type III), the latter shows the most favorable prognosis [3]. Furthermore, atypical patterns have been identified; plaque pattern, male pattern, and the ophiasis pattern [4-6].

Considering the fact that the exact cause remains unidentified, many factors have been proposed as potential triggers, such as environmental factors, dioxin-like substances present in animal-derived food and drugs, sun exposure, and viral infections, these factors have the potential to induce an inflammatory response in individuals who are genetically predisposed to such reactions [7]. Early identification of cases and initiation of treatment are crucial in avoiding

permanent scarring hair loss. In our retrospective study, we aimed to determine the relationship between the duration of the disease and response to the early initiation of different treatments. Additionally, we looked into the relation between facial papules and the duration of the disease.

METHODS

We conducted a retrospective study, including 16 cases of FFA from Tripoli Central Hospital, spanning from November 2019 to November 2023. In this study, we used data extracted from patients' follow-up records, which included information on demographics about gender, age, and race. disease history about; scalp distribution, duration, treatment response labeled as a poor or good response, and type of treatment, in our study different types of treatments were introduced with different combinations including; intralesional steroid, vibramycin, minoxidil, topical steroid cream, hydroxychloroquine, finstrid, protopic cream, and laser. examination of clinical types, presence of eyebrows alopecia and/or Facial papules or not, and trichoscopy findings. The process of data entry and analysis was conducted using SPSS 26. A Kendall's tau-b correlation was run to determine the relationship between the presence of facial papules and duration of disease, response to treatment, and duration of disease, considering a p-value less than 0.05 is statistically significant.

RESULTS

16 patients were recruited in the study. All of our patients were female 16 (100%), mostly Caucasian 15 (93.80%), the mean (SD) age was =53.50 (\pm 4.94), and all the cases presented with frontotemporal distribution with 10 (62.50%) of them having diffuse subtype (Figure 1). By Trichoscopy perifollicular scales and erythema were found simultaneously in 10 (62.50%) cases, and eyebrow alopecia and facial papules were present in 12 (75%) and 7 (43.8%) cases respectively (Figure 2,3). The median of disease duration in months was 54 (42-62). As outlined in table (1). Multi-treatment was applied to each patient, with an overlap in duration. We found intralesional steroid was used in 8 (50%), vibramycine in 7(43.8%), minoxidil in 6 (37.5%), topical steroid in 5 (31.3%), hydroxychloroquine in 5 (31.3%), finstrid in 5 (31.3%), protopic topical cream in 4 (25%), and laser in 3 (18.8%). There was a statistically significant negative strong association between the response to the treatment and the duration of the disease, $\tau_b = -0.574$, p-value = 0.011. Regarding the relation between facial papules and duration of the disease, there was a negative moderate association which was statistically insignificant, $\tau_b = -0.426$, p-value = 0.59.

Table 1. Demographic characteristics of study participants and clinical findings.

Parameter	Results (N=16)	
Age	Mean (SD)	53.50 (\pm 4.94)
	Median (Range)	54 (42-62)
Sex	Female	16 (100%)
	Male	0 (0%)
Scalp Distribution	Frontotemporal	16 (100%)
Clinical Types	Linear	5 (31.30%)
	Diffuse	10 (62.50%)
	Pseudofring	1 (6.3%)
Trichoscopy	Perifollicular Scales	5 (31.3%)
	Perifollicular Erythema	1 (6.30%)
	Perifollicular Scales and Erythema	10 (62.50%)
Skin Type	Caucasian	15 (93.80%)
	Black	1 (6.30%)
Duration (Months)	Mean (SD)	42 (\pm 43.46)
	Median (Range)	24 (3 - 132)
Clinical Findings		
	Yes	No
History Of Chronic Disease	12 (75%)	4 (25%)
Eyebrow Alopecia	12 (75%)	4 (25%)
Facial Papules	7 (43.8%)	9 (56.3%)

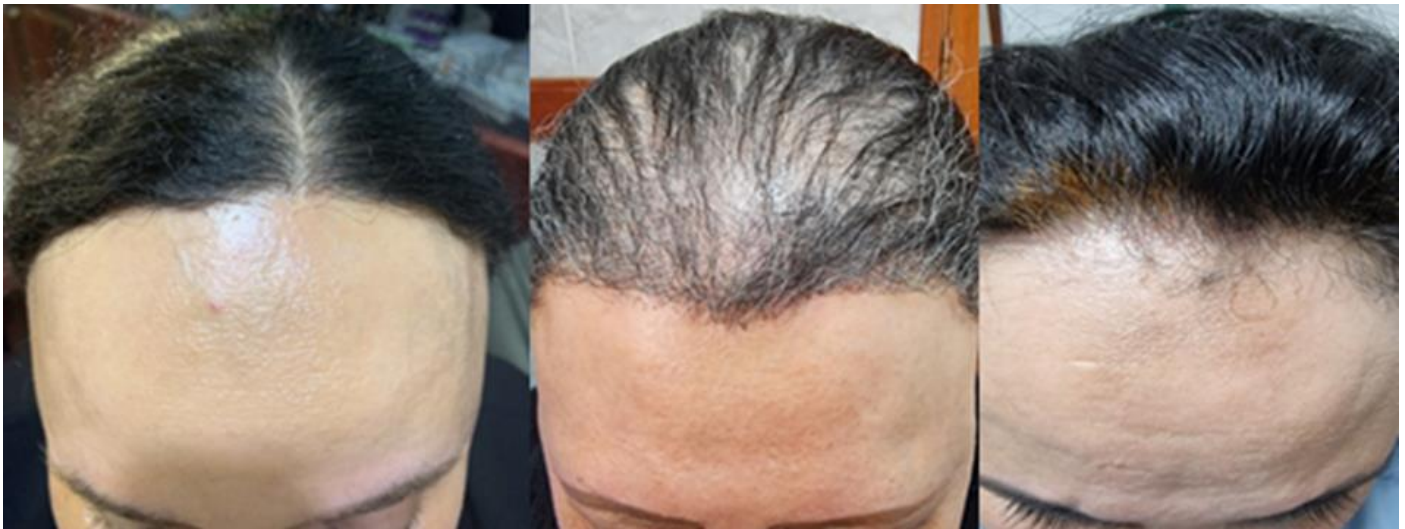

Figure 1. clinical types of FFA from left to right; linear type I, diffuse type II, pseudo-fringe type III.

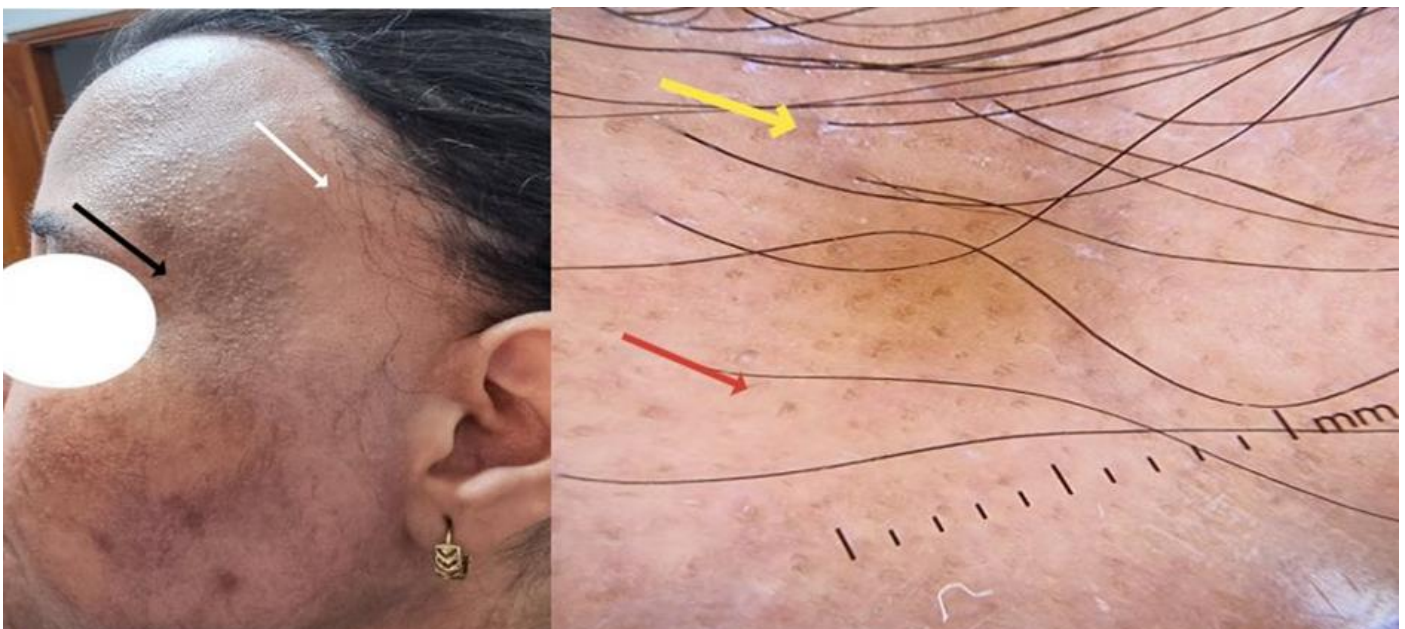


Figure 2. (Left) 48years old Female has pale shiny skin on the anterior hair line. facial papules black arrow, lonely hair white arrow. (Right) trichoscopic findings; yellow dots red arrow, perifollicular scales yellow arrow.

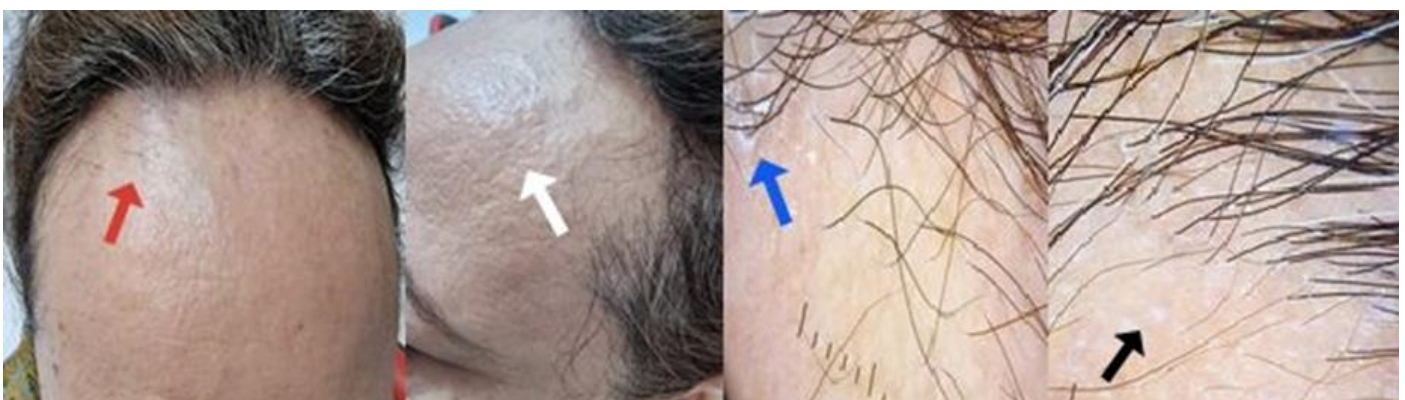

Figure 3. A 51-year- old female, picture shows pale and shiny skin with recession of anterior hair line and lonely hair; red arrow. Facial papules on temporal region; white arrow. Trichoscopic findings; perifollicular scales; blue arrow. White dots; black arrow.

DISCUSSION

Frontal Fibrosing Alopecia (FFA) is a rare type of cicatricial alopecia that involves the frontal line the diagnosis is made based on clinical findings and laboratory tests are rarely required. we aimed to determine the relation between the duration of the disease and response to early initiation of different treatments. We found a statistically significant association between starting early treatment and response to the disease, which suggests strong evidence that patients who are diagnosed and begin treatment early have a better treatment response compared to cases that are presented later. It's predicted that the initiation of early treatment can stop the progression of the fibrosing of hair follicles and reduce the risk of permanent hair loss.

The majority of our patients were females and most of them were Caucasian. Most of our patients' events started in menopause (women aged around 50 to 55 years old) which were similarly reported in previous studies [8], and this can be interpreted as an indication of the hormonal theory being one of the risk factors thus supporting the role of anti-androgen drugs and 5-alpha-reductase (5aRIs) in stabilizing the progress of the disease [8,9]. In all patients, the distribution was frontotemporal with involvement of the periauricular regions of the scalp with diffuse pattern in most of the patients (Figure 1). Even though atypical presentations weren't seen, they have different incidences, kanti et al., [10] conducted a cross-sectional study in France and Germany among 490 patients and reported ophiasis patterns were found in 32%. While rossi et al., [6] performed a retrospective mono-centric study and found ophiasis pattern in 6.1%, male pattern in 12.2%, and plaque pattern in 2%.

Trichoscopy findings were seen in all patients and perifollicular scales (peripilar casts) and erythema are reliable indicators of disease progression (Figure 2,3). Other clinical features were observed, the loss of eyebrows in most of the patients which is similar to a previous study [8], and facial papules in about half of the patients, in support of vellus and intermediate hair follicles [11].

Given the frequent association of FFA with autoimmune disorders like thyroid disease, vitiligo, lupus, Sjogren's Syndrome, and psoriasis, it is plausible to consider common causes that could be behind these conditions. [8, 11, 12]. A retrospective review of 60 patients conducted by Mac Donald et al., [8] in the United Kingdom where they found this association between FFA and autoimmune diseases in 30%, In our study it was observed in 75% of the cases. Hypothyroidism was reported more frequently in patients with FFA than in the general population (15% to 4.2%) [8]. Early identification of cases and initiation of treatment are crucial in avoiding permanent scarring hair loss, the first-line approach was super-potent topical corticosteroids and intra-lesional steroid injections. Additionally, 5% topical minoxidil applied once daily has been proven for its anti-fibrotic properties in diffuse female pattern hair loss with FFA [13,14]. If signs of active inflammation are identified through trichoscopy, additional treatment may be necessary. These treatment options may include the administration of hydroxychloroquine, vibramycin, or finasteride. Samrao et al., [7] reported a retrospective review of 36 patients and the efficacy of hydroxychloroquine and found a significant decrease of 73% of signs and symptoms in 15 patients who received hydroxychloroquine at 6-month follow-up. In our study, 5 patients who received hydroxychloroquine showed reduce in inflammation 4 of them showed poor response while only 1 patient showed little improvement. Furthermore, Navarini et al., [9] made research on 13 patients who were recruited from University Hospital of Zurich who showed no improvement with conventional treatments and found that the Excimer laser was useful in FFA and has been used to decrease inflammation. thus, Excimer laser treatments were performed twice weekly with a cumulative mean dose of 4,300 mj/cm².

CONCLUSION

Frontal fibrosing alopecia is a rare difficult disease, as its etiology remains unknown and it is frequently associated with autoimmune disorders. Further study of atypical types can assess accurate diagnosing, understating prognosis, and reach alternative treatment options, a comprehensive investigation into the pathophysiology and its mechanisms is needed.

Conflicts of Interest

There are no financial, personal, or professional conflicts of interest to declare.

REFERENCES

1. Kossard S. Postmenopausal Frontal Fibrosing Alopecia: Scarring Alopecia in a Pattern Distribution. *Archives of Dermatology*. 1994;130(6):770-4.
2. Jouanique C, Reygagne P. [Frontal fibrosing alopecia]. *Annales de dermatologie et de venereologie*. 2014;141(4):272-8.
3. Moreno-Arrones OM, Saceda-Corralo D, Fonda-Pascual P, Rodrigues-Barata AR, Buendía-Castaño D, Alegre-Sánchez A, et al. Frontal fibrosing alopecia: clinical and prognostic classification. *Journal of the European Academy of Dermatology and Venereology : JEADV*. 2017;31(10):1739-45.

4. Abdaljawad S, Qiteesh H, Abdelgader A, Saed W. Serum Ferritin Level and Alopecia Areata in Pediatric Patients. AlQalam Journal of Medical and Applied Sciences. 2022 Oct 30:527-33.
5. Contin LA, de Almeida Ledá YL, Caldeira Nassif K, Suárez Restrepo MV. Patchy Frontal Fibrosing Alopecia: Description of an Incomplete Clinical Presentation. Skin appendage disorders. 2017;3(4):190-2.
6. Rossi A, Grassi S, Fortuna MC, Garelli V, Pranteda G, Caro G, et al. Unusual patterns of presentation of frontal fibrosing alopecia: A clinical and trichoscopic analysis of 98 patients. Journal of the American Academy of Dermatology. 2017;77(1):172-4.
7. Samrao A, Chew AL, Price V. Frontal fibrosing alopecia: a clinical review of 36 patients. The British journal of dermatology. 2010;163(6):1296-300.
8. MacDonald A, Clark C, Holmes S. Frontal fibrosing alopecia: a review of 60 cases. Journal of the American Academy of Dermatology. 2012;67(5):955-61.
9. Navarini AA, Kolios AG, Prinz-Vavricka BM, Haug S, Trüeb RM. Low-dose excimer 308-nm laser for treatment of lichen planopilaris. Arch Dermatol. 2011;147(11):1325-6.
10. Kanti V, Constantinou A, Reygagne P, Vogt A, Kottner J, Blume-Peytavi U. Frontal fibrosing alopecia: demographic and clinical characteristics of 490 cases. Journal of the European Academy of Dermatology and Venereology: JEADV. 2019;33(10):1976-83.
11. Tosti A, Piraccini BM, Iorizzo M, Misciali C. Frontal fibrosing alopecia in postmenopausal women. Journal of the American Academy of Dermatology. 2005;52(1):55-60.
12. Tan KT, Messenger AG. Frontal fibrosing alopecia: clinical presentations and prognosis. The British journal of dermatology. 2009;160(1):75-9.
13. Secchin P, Quintella DC, Paula NÁ O, Andrade L, Sodré CT. Clinical-histopathological profile of the frontal fibrosing alopecia: a retrospective study of 16 cases of a university hospital. Anais brasileiros de dermatologia. 2019;94(4):416-21.
14. Gkini MA, Riaz R, Jolliffe V. A Retrospective Analysis of Efficacy and Safety of Intralesional Triamcinolone Injections in the Treatment of Frontal Fibrosing Alopecia Either as Monotherapy or as a Concomitant Therapy. International journal of trichology. 2018;10(4):162-8.

أهمية العلاج المبكر لمرض الثعلبة الليفية الأمامية

سجى لاغا^{1*}، فوزية مصباح¹، محمد طبيب²

¹قسم الأمراض الجلدية، مستشفى طرابلس المركزي، طرابلس، ليبيا.
²قسم الباطنية، مستشفى طرابلس المركزي، طرابلس، ليبيا.

المستخلص

الثعلبة الليفية الأمامية وهي أحد أشكال ثعلبة الحزاز المسطحة وصفت كتراجعا تدريجيا يؤثر على منطقة الجبهة لدى النساء بعد فترة انقطاع الطمث، مع وجود اختلاف بين الجلد الأملس والجلد التالف بسبب الشمس على الجبهة، من خلال منظار الشعر، هناك نقص في فتحات بصليات الشعر ووجود احمرار حولها عند خط الشعر الأمامي. مع السمات المرضية التي تشمل التسلل الليمفاوي وتليف الطبقة الجذرية لبصليات الشعر. هدفا إلى تحديد العلاقة بين مدة المرض والاستجابة للبدء المبكر في علاجات مختلفة. أجرينا دراسة بأثر رجعي، شملت 16 حالة من الثعلبة الليفية الأمامية من مستشفى طرابلس المركزي، امتدت من نوفمبر 2019 إلى نوفمبر 2023. في هذه الدراسة، استخدمنا البيانات المستخرجة من سجلات متابعة المرضى، والتي تضمنت معلومات عن التركيبة السكانية وتاريخ المرض ونتائج الفحص ونتائج تنظير الشعر والعلاجات المقدمة. تم إجراء عملية إدخال البيانات وتحليلها باستخدام برنامج SPSS 26. وجدنا من بين 16 مشاركا كانوا جميعا من الإناث، متوسط أعمارهم 53.50 (±4.94)، وكان تاريخ المدة بالأشهر 54 (42-62). كان هناك ارتباط قوي سلبي ذو دلالة إحصائية بين الاستجابة للعلاج ومدة المرض، $\tau b = -0.574$ ، قيمة $p = 0.011$.
الكلمات الدالة: الثعلبة الليفية الجبهية، الثعلبة الندبية، تنظير الشعر، دراسة بأثر رجعي.