Alqalam Journal of Medical and Applied Sciences. 2026;9(11):3947-3953
https://doi.org/10.54361/ajmas.261153

Original article

Effects of Virgin Olive Oil on Oxidative Stress and Cardiovascular Histopathology in Induced Hyperlipidaemic Rats

Aasim Alshaibi[1], Mohamed Aborokia[2], Ali Aghwider*[3]

[1]*Department of Internal Medicine, Faculty of Medicine, University of Zintan, Zintan, Libya*
[2]*Department of Basic Nursing, College of Nursing, University of Tripoli, Tripoli, Libya*
[3]*Department of Anaesthesia and Intensive Care, Faculty of Medical Technology, Azzytuna University, Tarhuna, Libya*
Email. *Ali.Aghwider@azu.edu.ly*

Abstract
Hyperlipidaemia can contribute to cardiovascular damage through oxidative stress, lipid peroxidation, and inflammation of vascular tissues, potentially resulting in structural alterations in the myocardium and arterial walls. Virgin olive oil (VOO) contains monounsaturated fatty acids and phenolic compounds with antioxidant and cardioprotective properties. This study aimed to investigate the potential protective effects of virgin olive oil against hyperlipidaemia-induced oxidative stress and histopathological alterations in the heart and thoracic aorta of male rats. Fifty male Sprague–Dawley rats were randomly allocated into five experimental groups receiving different dietary regimens: a normal diet, a hyperlipidaemic diet, a hyperlipidaemic diet supplemented with low-dose virgin olive oil, a hyperlipidaemic diet supplemented with high-dose virgin olive oil, and a dietary recovery regimen. The experimental period lasted four weeks. The activities of superoxide dismutase (SOD), glutathione peroxidase (GPx), and catalase (CAT) were measured in blood cell lysates, while serum malondialdehyde (MDA) levels were assessed as an indicator of lipid peroxidation. Histopathological examinations of heart and thoracic aorta specimens were also performed using haematoxylin and eosin (H&E) staining. The hyperlipidaemic diet significantly decreased SOD, GPx, and CAT activities and increased serum MDA levels compared with the normal diet group ($P \leq 0.05$). Virgin olive oil supplementation significantly improved antioxidant enzyme activities and reduced lipid peroxidation in hyperlipidaemic rats, with more pronounced effects observed in the high-dose group ($P \leq 0.05$). Histopathological examination also revealed that virgin olive oil supplementation attenuated hyperlipidaemia-associated structural alterations in the myocardium and thoracic aorta, with the greatest improvement observed in the high-dose group. In conclusion, virgin olive oil supplementation attenuated hyperlipidaemia-induced oxidative stress and reduced histopathological damage to the heart and thoracic aorta in rats, with effects suggesting a dose-dependent protective response. These findings support the potential antioxidant and cardioprotective properties of virgin olive oil. However, further experimental and clinical studies are required to establish the underlying mechanisms and confirm its protective effects in humans.
Keywords. Virgin Olive Oil, Hyperlipidaemia, Oxidative Stress, Antioxidant Enzymes, Cardiovascular Histopathology.

Introduction

Cardiovascular diseases have always been a major global cause of morbidity and mortality. Hyperlipidaemia is the most common modifiable determinant of risk of atherosclerotic cardiovascular disease [1,2]. Sustained alterations in lipid metabolism can induce endothelial dysfunction, inflammation, oxidative stress, and lipid accumulation within the arterial wall, which then leads to the acceleration of the atherosclerotic process and cardiovascular damage [2-4].

One of the important mechanisms by which hyperlipidaemia induces myocardial and vascular injury is oxidative stress, due to increased production of reactive oxygen species (ROS), which can overcome endogenous antioxidant defence systems, including SOD, GPx and CAT, and induce lipid peroxidation and cell damage [4-6]. MDA is one product of lipid peroxidation commonly employed as a marker of oxidative injury in experimental and clinical studies [5].

Extra virgin olive oil, an ingredient in the Mediterranean eating regimen, supplies monounsaturated fatty acids (primarily oleic acid) and a mix of bioactive phenolic constituents like tyrosol, hydroxytyrosol, and oleuropein derivatives, which might have antioxidant, anti-inflammatory, antiatherogenic, and endothelial-modulatory impacts [7-9]. Observational evidence continues to strengthen the position of extra virgin olive oil usage and the Mediterranean eating plan as health-promoting foods by linking their use to a reduced risk of cardiovascular issues, along with laboratory proof demonstrating their protective roles against vascular and oxidative damage [7-9].

Thus, the aim of the present study was to assess the impact of both low and high doses of virgin olive oil administration on activities of antioxidant enzymes, MDA, and histopathological changes in the heart and thoracic aorta in hyperlipidaemic rats induced by diet.

Materials and Methods

Animals and Experimental Design

Apparently healthy male Sprague–Dawley rats (n = 50), initially weighing 90–110 g, were used in the current investigation. Animals were kept in standard commercial cages equipped with automatic drinking and feeding systems, where they acclimatised under environmental conditions of 22–25 °C and a 14-hour light/10-hour dark cycle at the animal house of the

Copyright *Author (s) 2026. Distributed under Creative Commons CC BY 4.0*
Received*: 19-09-2026 -* ***Accepted****: 18-11-2026 -* ***Published****: 25-11-2026*

Faculty of Veterinary Medicine at Azzytuna University, Libya. All experimental manipulations conformed to the guidelines of the Bioethics Committee at the Biotechnology Research Centre, Tripoli, Libya (ref number: NBC: 001.A.26.52).

Induction of hyperlipidaemia

Hyperlipidaemia was artificially induced by feeding the specified groups of rats with a high-fat diet for three weeks prior to the treatment period. The composition of the high-fat content in the experimental diet includes 20 g of fat/100 g of diet and 19 g of butter oil + 1 g of soybean oil/100 g of diet. The formulation of fat was designed following modifications to standard diets [11].

Olive oil

The olive oil used in this study was purchased from an olive field produced in Tarhuna, Libya, which produces the fruit Olea europaea L. (family Oleaceae) olives as identified by the Agriculture Research Centre (ARC); fatty acid profile (C16:0 (11.32 g/100 g), C16:1 (n-9) (0.11 g/100 g), C16:1 (n-7) (0.84 g/100 g), C18:0 (4.34 g/100 g), C18:1 (n-9) (74.12 g/100 g), C18:2 (n-6) (7.64 g/100 g), and C18:3 (n-3) (0.61 g/100 g)). The two olive oil groups received virgin olive oil by gastric gavage at 1 mL or 2 mL per 100 g body weight, respectively, during the 30-day intervention.

Blood collection and serum preparation

Blood samples were withdrawn at four weekly assessments during the 30-day intervention from experimental animals early in the morning before feeding and drinking in plainly labelled tubes. The blood samples were divided into two sets, and one tube (in a heparinised state) was used for obtaining whole-blood cell lysate after appropriate treatment in order to determine the antioxidant parameter, and in another (plain tube), the blood was allowed to clot by keeping it at room temperature; after that, the serum was obtained after centrifugation at 3000 rpm for 30 min. The clear, non-haemolysed serum was collected and preserved at −20 °C until the biochemistry was performed.

Oxidative stress and antioxidant assays

Determination of superoxide dismutase activity (SOD) in blood cell lysate was made using a commercially available kit purchased from Bio-Diagnostic, Egypt [15].
Determination of glutathione peroxidase activity (GPx) in blood-cell lysates was measured using a commercially available kit purchased from Bio-Diagnostic kit [14].
Determination of catalase activity (CAT) was measured in blood-cell lysates using the method of Aebi [16].
Determination of serum malondialdehyde (MDA) was measured using a spectrophotometer with a commercial Bio-Diagnostic kit designed to estimate lipid peroxidation [13].

Histopathological investigation

At the end of the 30-day intervention, the animals were euthanised, and samples of the heart and thoracic aorta were processed for histopathological examination. Tissue samples were preserved in 10% neutral buffered formalin, then dehydrated in rising grades of ethanol, followed by clearing in xylene and embedding in paraffin wax. The embedded tissues were cut into serial sections of 5–6 µm in thickness and stained with haematoxylin and eosin (H&E) for histopathological examination with light microscopy [17].

Statistical analysis

The data are shown as the mean ± standard error of the mean. In the original analysis, the results were analysed using a two-way analysis of variance in CoStat version 6.400 with the least significant difference test. P-values ≤ 0.05 were considered significant [18].

Results and Discussion

The activities of superoxide dismutase (SOD), glutathione peroxidase (GPx), and catalase (CAT) significantly decreased, while serum malondialdehyde (MDA) concentrations were significantly increased in hyperlipidemic (HD) animals as compared to the normal diet (ND) group in four weekly measurements ($P \leq 0.05$). Administration of either low-dose or high-dose virgin olive oil restored the antioxidant profile of the HD group toward normal. SOD and CAT activities were highest in the HD + HVOO group. MDA concentrations were decreased in both oil-treated groups. These findings are presented in Table 1 and Figures 1–4.
Rats fed a hyperlipidemic diet showed decreased SOD, GPx, and CAT activities and increased serum MDA concentrations. The high-fat diet resulted in increased plasma lipid levels, which induced oxidative stress that hindered the production and elimination of oxidizing agents. These data are in accordance with previous reports on the decreased SOD, GPx, and CAT activities in rats fed a hyperlipidemic diet. However, they are contrary to studies that show no change in SOD and CAT activities in rabbits fed cholesterol. The role of saturated fat in a cholesterol-atherogenic diet may clarify these discrepancies. Unlike the control group, saturated fat reduced SOD and CAT mRNA levels in animals with liver damage [5]. The addition of low-dose virgin

Copyright *Author (s) 2026. Distributed under Creative Commons CC BY 4.0*
Received*: 19-09-2026 -* ***Accepted****: 18-11-2026 -* ***Published****: 25-11-2026*

https://doi.org/10.54361/ajmas.261153

olive oil (LVOO) or high-dose virgin olive oil (HVOO) to the diet of hyperlipidaemic rats improved SOD and CAT activities and significantly decreased MDA concentrations. The benefits of virgin olive oil may be due to its higher contents of free radical-scavenging carotenoids, tocopherols, phenolic compounds (PhCs), and polyphenols. Some phenolic compounds in virgin olive oil, such as oleuropein, tyrosol, hydroxytyrosol, and caffeic acid, may decrease the oxidation of low-density lipoprotein cholesterol (LDL-C). These results support previous claims that phenolic compounds found in green and black olives decrease lipid peroxidation and enhance antioxidant defense. Research suggests that olive oil lowers MDA concentrations in hyperlipidaemic rats on a cholesterol-rich diet [7].

Table 1. Changes in Oxidative Stress and Antioxidant Biomarkers Across Experimental Groups During the Study Period

Parameters	Groups	ND	HD	HD + LVOO	HD + HVOO	HD + ND	LSD
SOD (U/mg)	I	46.58 ± 1.40	30.44 ± 2.44	34.88 ± 1.78	35.98 ± 2.23	29.78 ± 2.30	2.52
	II	47.51 ± .18	30.27 ± 2.54	37.46 ± 1.77	39.58 ± 2.18	30.66 ± 2.09	
	III	47.94 ±1.26	28.07 ± 2.75	39.52 ± 1.84	41.12 ± 2.30	30.76 ± 2.20	
	IV	48.38 ± 1.41	27.42 ± 3.13	42.10 ± 1.79	43.82 ± 1.75	32.12 ± 3.02	
GPx (U/mg)	I	20.58 ± 1.36	11.34 ± 1.63	12.08 ± 0.95	13.60 ± 1.57	10.86 ± 1.59	N.S
	II	21.18 ± 1.41	11.62 ± 0.74	12.38 ± 0.89	13.82 ± 1.54	11.84 ± 1.29	
	III	22.00 ± 1.62	10.41 ± 1.63	12.08 ± 1.48	14.52 ± 0.99	10.86 ± 1.89	
	IV	20.58 ± 1.36	11.34 ± 1.63	12.08 ± 0.95	13.60 ± 1.57	11.84 ± 1.59	
CAT (U/mg)	I	22.94 ± 0.95	16.92 ± 1.24	14.52 ± 0.99	14.52 ± 0.99	12.26 ± 1.99	2.11
	II	23.07 ± 1.12	16.56 ± 1.47	12.26 ± 1.99	13.60 ± 1.57	12.26 ± 1.99	
	III	23.22 ± 1.02	16.38 ± 1.48	14.19 ± 2.35	14.19 ± 0.99	12.26 ± 1.99	
	IV	23.42 ± 1.36	15.19 ± 1.97	15.82 ± 1.79	15.82 ± 1.92	14.92 ± 2.86	
MDA (nmol/mg protein	I	18.71 ± 1.18	32.85 ± 1.03	19.61 ± 1.22	19.61 ± 1.22	21.20 ± 1.37	N.S
	II	18.84 ± 1.32	23.38 ± 0.92	20.21 ±1.17	20.21 ± 1.40	21.42 ± 1.79	
	III	19.42 ± 1.34	24.14 ± 0.84	20.60 ± 1.27	20.60 ± 1.17	21.59 ± 1.37	
	IV	19.42 ± 1.34	25.01 ± 1.16	21.67 ± 1.07	21.67 ± 1.27	24.74 ± 1.47	

Values are mean ± standard error (n = 10 per group). ND = normal-diet control, HD = hyperlipidaemic diet, HD + LVOO = HD with low-dose virgin olive oil, HD + HVOO = HD with high-dose virgin olive oil, and HD + ND = hyperlipidaemic rats switched to a normal diet. I–IV = weeks 1–4. LSD = least significant difference, N.S. = not significant.

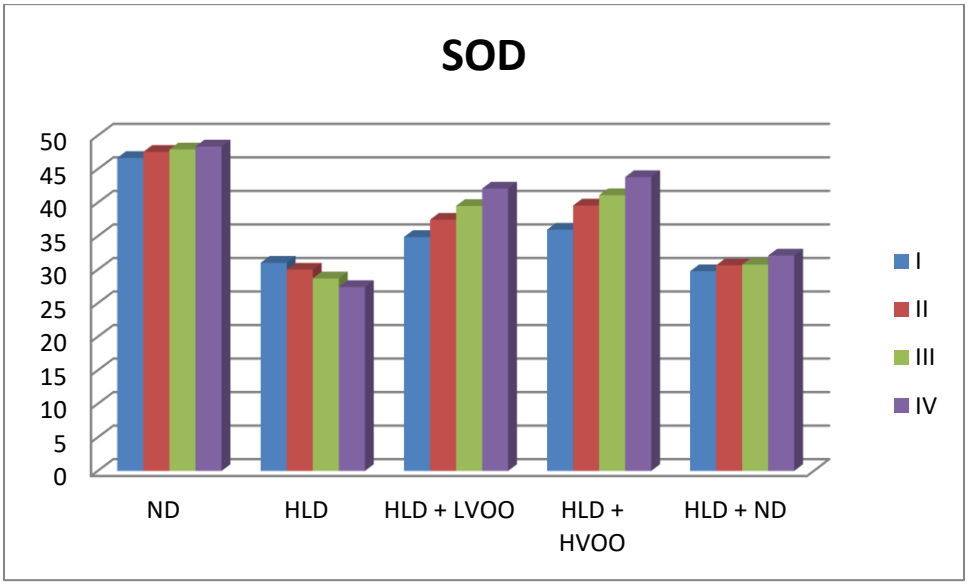

Figure 1. SOD activity in blood-cell lysates of rats by group and week.

ND = Normal-diet control, HD = Hyperlipidaemic diet, HD + LVOO = Hyperlipidaemic diet + low dose of virgin olive oil, HD + HVOO = Hyperlipidaemic diet + high dose of virgin olive oil, HD + ND = hyperlipidaemic rats switched to a normal diet, I = 1st week, II = 2nd week, III = 3rd week, and IV = 4th week.

Copyright *Author (s) 2026. Distributed under Creative Commons CC BY 4.0*
Received*: 19-09-2026 -* ***Accepted****: 18-11-2026 -* ***Published****: 25-11-2026*

https://doi.org/10.54361/ajmas.261153

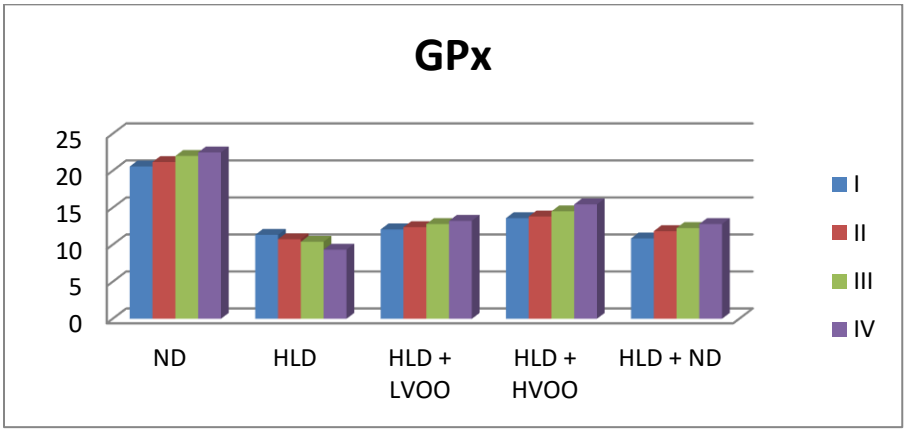

Figure 2. GPx activity in blood-cell lysates of rats by group and week.

ND = Normal-diet control, HD = Hyperlipidaemic diet, HD + LVOO = Hyperlipidaemic diet + low dose of virgin olive oil, HD + HVOO = Hyperlipidaemic diet + high dose of virgin olive oil, HD + ND = hyperlipidaemic rats switched to a normal diet, I = 1st week, II = 2nd week, III = 3rd week, and IV = 4th week.

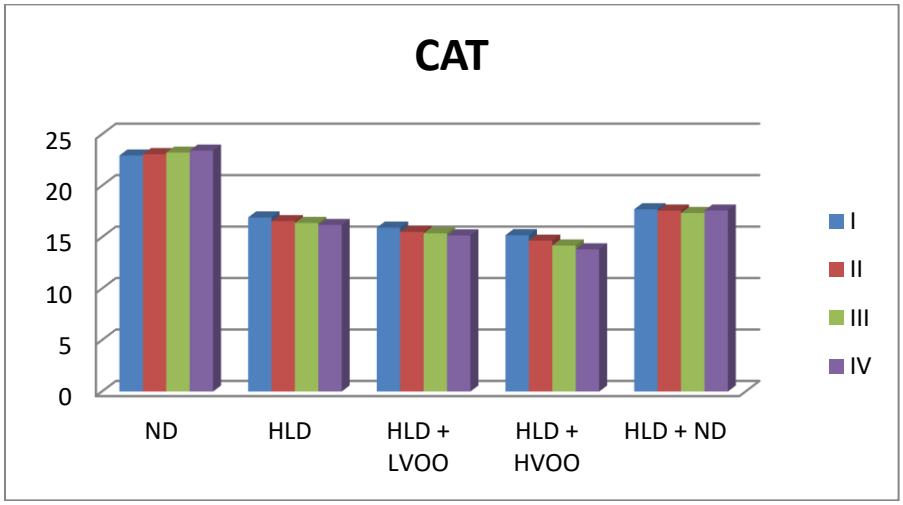

Figure 3. CAT activity in blood-cell lysates of rats by group and week.

ND = Normal-diet control, HD = Hyperlipidaemic diet, HD + LVOO = Hyperlipidaemic diet + low dose of virgin olive oil, HD + HVOO = Hyperlipidaemic diet + high dose of virgin olive oil, HD + ND = hyperlipidaemic rats switched to a normal diet, I = 1st week, II = 2nd week, III = 3rd week, and IV = 4th week.

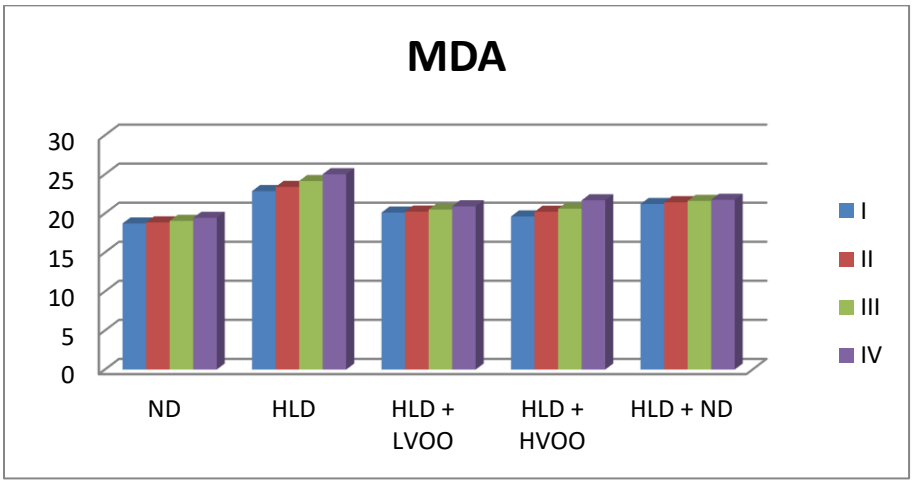

Figure 4. Serum MDA concentrations in rats by group and week.

ND = Normal-diet control, HD = Hyperlipidaemic diet, HD + LVOO = Hyperlipidaemic diet + low dose of virgin olive oil, HD + HVOO = Hyperlipidaemic diet + high dose of virgin olive oil, HD + ND = hyperlipidaemic rats switched to a normal diet, I = 1st week, II = 2nd week, III = 3rd week, and IV = 4th week.

Copyright *Author (s) 2026. Distributed under Creative Commons CC BY 4.0*
Received*: 19-09-2026 -* ***Accepted****: 18-11-2026 -* ***Published****: 25-11-2026*

https://doi.org/10.54361/ajmas.261153

Histopathological findings

The ND group showed normal myocardial architecture (Figure 5a). The HD group showed focal mononuclear infiltration, hydropic degeneration, and vacuolation (Figure 5b). Focal mononuclear infiltration was still present in the HD + LVOO group (Figure 5c). The HD + HVOO and HD + ND groups showed nearly normal myocardial morphology in the representative sections (Figure 5d,e).

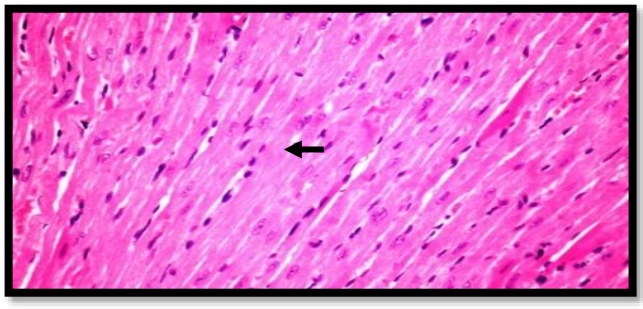

a- Heart showing normal myocardium features (H&E x200).

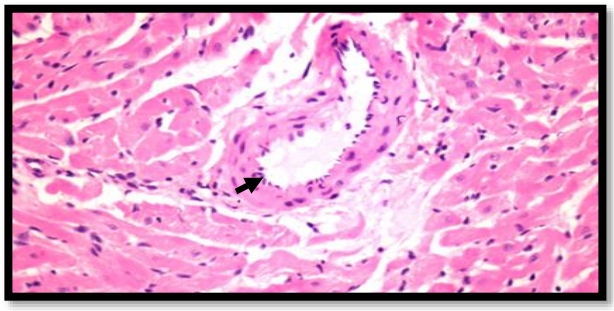

b- Heart B.V. showing myocardium changes in the form of a focal area of mononuclear infiltration and hydropic degeneration and vacuolation (H&E x 200).

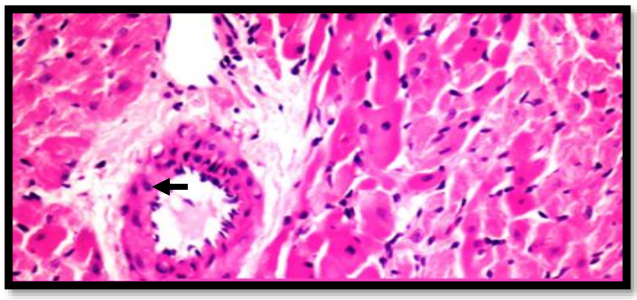

c-Heart showing markedly myocardium changes in the form of a focal area of mononuclear cell infiltrations (H&E x200).

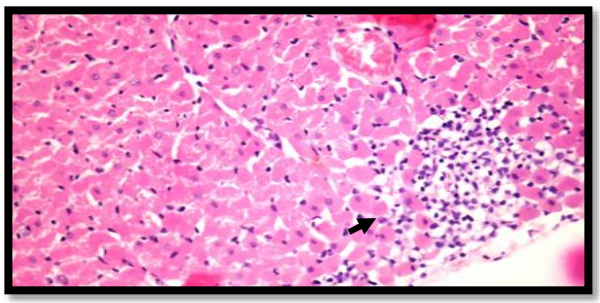

d-Heart showing nearly normal myocardium features (H&E x 200).

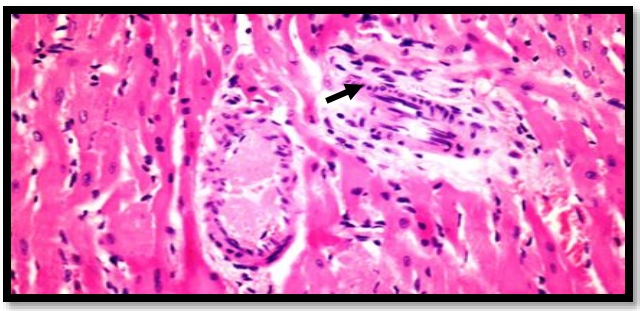

e-Heart showing nearly normal myocardium features (H&E x200).

Figure 5. Effect of olive oil on the histopathology of the heart of hyperlipidaemic rats.
a = ND, b = HD, c = HD + LVOO, d = HD + HVOO, e = HD + ND

The ND group showed a normal thoracic aortic wall and a patent lumen (Figure 6a). The HD group showed atheroma, segmental wall thickening, and luminal narrowing (Figure 6b). Wall thickening and luminal narrowing persisted in the HD + LVOO group (Figure 6c). The HD + HVOO group showed a nearly normal aortic wall and a wider lumen (Figure 6d). The HD + ND group showed wall thickening, luminal narrowing, and severe congestion (Figure 6e).

Copyright *Author (s) 2026. Distributed under Creative Commons CC BY 4.0*
Received*: 19-09-2026 -* ***Accepted****: 18-11-2026 -* ***Published****: 25-11-2026*

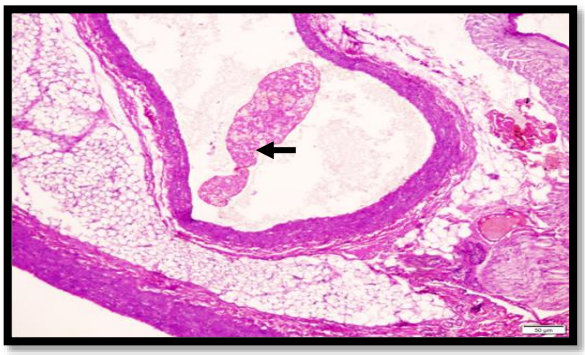

a- The aorta showing apparently normal arterial wall and large lumen, with no abnormalities (H&E x 40).

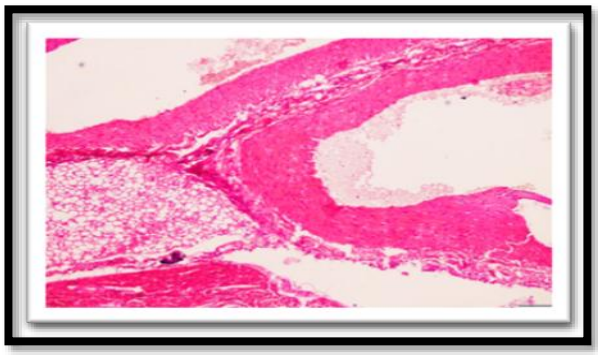

b- The aorta showing atherosclerotic changes in the form of atheroma, with segmental thickening of the wall with narrowed lumen (arrow). (H&E x 40).

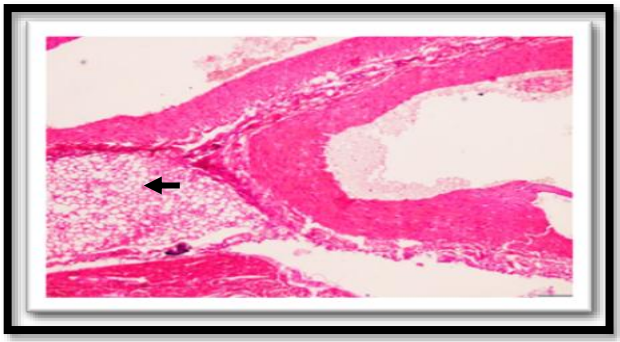

c- The aorta showing markedly atherosclerotic changes in the form of a thickened arterial wall with a narrowed lumen (H&E x 40).

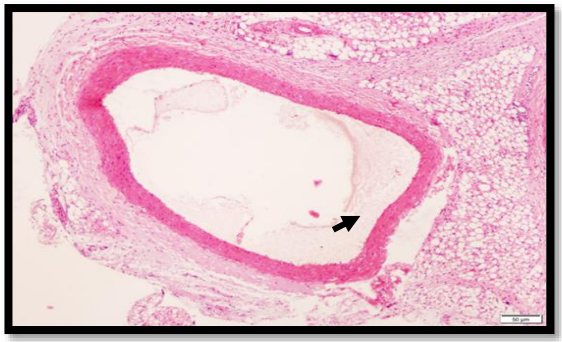

d- The aorta showing nearly normal wall and dilatation in the lumen (H&E x 40).

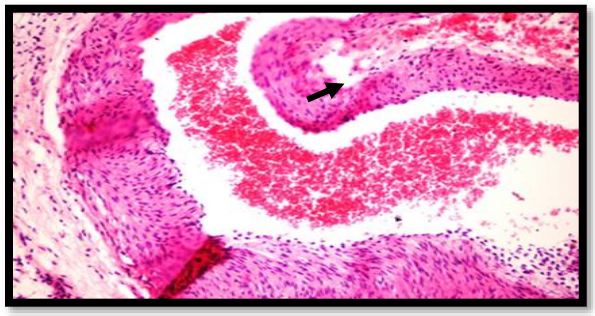

e- The aorta showing thickening of the arterial wall with a narrowed lumen and severe congestion (H&E x 40).

Figure 6. Effect of olive oil on the histopathology of the aorta of hyperlipidaemic rats.
a = ND, b = HD, c = HD + LVOO, d = HD + HVOO, e = HD + ND

Inflammation of the vessels and oxidative stress are typical features of atherosclerotic cardiovascular disease. The lack of antioxidant enzymes decreases the organism's power to fight oxidising agents. Elevated MDA concentrations signify membrane lipid peroxidation [5,6].

In hyperlipidaemic rats, virgin olive oil supplementation was associated with higher mean SOD and GPx activities and lower mean serum MDA concentrations than the hyperlipidaemic diet alone. The lower mean CAT activity in supplemented rats indicates that the enzyme responses differed. Oleic acid and phenolic compounds such as hydroxytyrosol and secoiridoids may contribute to some of these effects [7]. The representative sections showed the most consistent preservation of myocardial and aortic morphology in the high-dose group. Rats switched to the normal diet showed nearly normal myocardial morphology and persistent aortic alterations. The histological observations are qualitative. Longer follow-up would help determine whether the biochemical and histological patterns persist.

Conclusion

In rats with diet-induced hyperlipidaemia, virgin olive oil supplementation was associated with higher mean SOD and GPx activities and lower mean serum MDA concentrations than the hyperlipidaemic diet alone. Mean CAT activity was lower in both

Copyright *Author (s) 2026. Distributed under Creative Commons CC BY 4.0*
Received*: 19-09-2026 -* ***Accepted****: 18-11-2026 -* ***Published****: 25-11-2026*

supplemented groups. The high-dose group showed nearly normal myocardial and aortic morphology in representative sections. Further research is needed to establish the durability and clinical relevance of these findings.

References

1. Roth GA, Mensah GA, Johnson CO, Addolorato G, Ammirati E, Baddour LM, et al. Global burden of cardiovascular diseases and risk factors, 1990-2019: update from the GBD 2019 Study. J Am Coll Cardiol. 2020;76(25):2982-3021. doi:10.1016/j.jacc.2020.11.010
2. Mach F, Baigent C, Catapano AL, Koskinas KC, Casula M, Badimon L, et al. 2019 ESC/EAS Guidelines for the management of dyslipidaemias: lipid modification to reduce cardiovascular risk. Eur Heart J. 2020;41(1):111-188. doi:10.1093/eurheartj/ehz455
3. Libby P. The changing landscape of atherosclerosis. Nature. 2021;592(7855):524-533. doi:10.1038/s41586-021-03392-8
4. Steven S, Frenis K, Oelze M, Kalinovic S, Kuntic M, Bayo Jimenez MT, et al. Vascular inflammation and oxidative stress: major triggers for cardiovascular disease. Oxid Med Cell Longev. 2019;2019:7092151. doi:10.1155/2019/7092151
5. Ayala A, Munoz MF, Arguelles S. Lipid peroxidation: production, metabolism, and signaling mechanisms of malondialdehyde and 4-hydroxy-2-nonenal. Oxid Med Cell Longev. 2014;2014:360438. doi:10.1155/2014/360438
6. He L, He T, Farrar S, Ji L, Liu T, Ma X. Antioxidants maintain cellular redox homeostasis by elimination of reactive oxygen species. Cell Physiol Biochem. 2017;44(2):532-553. doi:10.1159/000485089
7. Ussia S, Ritorto G, Mollace R, Serra M, Tavernese A, Altomare C, et al. Exploring the benefits of extra virgin olive oil on cardiovascular health enhancement and disease prevention: a systematic review. Nutrients. 2025;17(11):1843. doi:10.3390/nu17111843
8. Guasch-Ferre M, Hu FB, Martinez-Gonzalez MA, Fito M, Bullo M, Estruch R, et al. Olive oil intake and risk of cardiovascular disease and mortality in the PREDIMED Study. BMC Med. 2014;12:78. doi:10.1186/1741-7015-12-78
9. Estruch R, Ros E, Salas-Salvado J, Covas MI, Corella D, Aros F, et al. Primary prevention of cardiovascular disease with a Mediterranean diet supplemented with extra-virgin olive oil or nuts. N Engl J Med. 2018;378(25):e34. doi:10.1056/NEJMoa1800389
10. National Research Council (US). Nutrient requirements of laboratory animals. 2nd ed. Washington (DC): National Academy of Sciences; 1977.
11. Woods SC, Seeley RJ, Rushing PA, D'Alessio D, Tso P. A controlled high-fat diet induces an obese syndrome in rats. J Nutr. 2003;133(4):1081-1087.
12. AOAC International. Official methods of analysis. 19th ed. Gaithersburg (MD): AOAC International; 2012.
13. Esterbauer H, Cheeseman KH. Determination of aldehydic lipid peroxidation products: malonaldehyde and 4-hydroxynonenal. Methods Enzymol. 1990;186:407-421. doi:10.1016/0076-6879(90)86134-H
14. Paglia DE, Valentine WN. Studies on the quantitative and qualitative characterization of erythrocyte glutathione peroxidase. J Lab Clin Med. 1967;70(1):158-169.
15. Nishikimi M, Rao NA, Yagi K. The occurrence of superoxide anion in the reaction of reduced phenazine methosulfate and molecular oxygen. Biochem Biophys Res Commun. 1972;46(2):849-854.
16. Aebi H. Catalase in vitro. Methods Enzymol. 1984;105:121-126. doi:10.1016/S0076-6879(84)05016-3
17. Bancroft JD, Stevens A. Theory and practice of histological techniques. 4th ed. Edinburgh: Churchill Livingstone; 1996.
18. Snedecor GW, Cochran WG. Statistical methods. 7th ed. Ames (IA): Iowa State University Press; 1980.

Copyright *Author (s) 2026. Distributed under Creative Commons CC BY 4.0*
Received*: 19-09-2026 -* ***Accepted****: 18-11-2026 -* ***Published****: 25-11-2026*