Alqalam Journal of Medical and Applied Sciences. 2026;9(11):3874-3887
https://doi.org/10.54361/ajmas.261146

Original article

Brain MRI Findings in Children with Developmental Delay: A Retrospective Cross-Sectional Study from a Tertiary Center in Libya

Fatma Abusaa, Yousef Elshrimi*, Fatima Alajtel, Suad Endish

Department of Diagnostic Radiology, Misratah Medical Center, Misratah, Libya
Email. elshrimi@gmail.com

Abstract
Libyan data on the yield of brain magnetic resonance imaging (MRI) in children with developmental delay are lacking. We aimed to estimate the proportion of abnormal scans, describe the pattern of findings, and compare the yield by sex, age, and gestational maturity. This retrospective cross-sectional study reviewed 118 children (63 boys; ages 1 month to 14 years) who had brain MRI for developmental delay at Misratah Medical Center in 2019–2023. Four radiologists read the scans independently, with the clinical notes available, and entered the findings on a structured form. An abnormal MRI was any abnormal form entry or non-normal conclusion; a strict definition excluded isolated normal variants. We used Wilson confidence intervals (CI), Fisher's exact test, and logistic regression. MRI was abnormal in 70 children (59.3%; 95% CI 50.3–67.8) and in 54.2% by the strict definition. White matter lesions (28.8%) and corpus callosum abnormalities (16.9%) were the commonest findings, and ischemic or hypoxic white matter injury was the commonest pattern (13.6%). Abnormal MRI was more frequent in girls than in boys (70.9% vs 49.2%; adjusted odds ratio (OR) 3.08, 95% CI 1.36–6.95) and in children younger than 3 years than in children aged 3 years or older (69.2% vs 47.2%; adjusted OR 3.08, 95% CI 1.38–6.89); the age difference weakened under the strict definition (p = 0.096). Among 45 children with documented maturity, all nine preterm children had an abnormal MRI, compared with 61.1% of term children (p = 0.040). About three in five children referred for developmental delay had an abnormal MRI, most often with a white matter abnormality. Girls and children younger than 3 years had a higher yield. These exploratory findings need confirmation in prospective, multicenter studies that record clinical data.
Keywords. Developmental Delay, Magnetic Resonance Imaging, Neuroimaging, Child, White Matter, Libya.

Introduction

Developmental delays are common, and their burden falls mainly on low- and middle-income countries. In 2016, an estimated 52.9 million children younger than 5 years had a developmental disability, about 95% of them in those countries [1]. Global developmental delay, a significant delay in two or more developmental domains, affects an estimated 1% to 3% of children [2,3]. Neuroimaging forms part of the search for a cause. The 2003 American Academy of Neurology practice parameter recommended neuroimaging in global developmental delay, with magnetic resonance imaging (MRI) preferred over computed tomography (CT), particularly when the examination is abnormal [2]. A later American Academy of Pediatrics report put the proportion of children with abnormal MRI at about 30%; nine MRI studies it reviewed ranged from 6.2% to 48.7%, and yield was higher when neurological signs were present [3]. A systematic review of 29 studies, covering 2,299 children with isolated global developmental delay or intellectual disability, found abnormal MRI in 38% (study rates 0% to 98%) and an etiological diagnosis in 7.9%; its authors noted that definitions of an abnormal scan varied widely [4]. General reviews cover the clinical assessment and investigation of developmental delay [5] and the imaging of affected children [6].

Series from the Middle East, Africa and South Asia report higher figures: 54.7% and 70% in Saudi Arabia [7,8], 58.6% in Iran [9], 60.6% to 87.5% in six Indian series [10–15], 73.2% in Ethiopia [16] and 82% in Egypt [17]. Neurovascular injury, mostly hypoxic–ischemic, was the leading finding in several of them [9–13,16]. These series differ in age range, referral pattern, and the definition of an abnormal scan, so their yields cannot be transferred to another country.

Little is known about Libya. The one neuroimaging series we found from the country, from Tripoli, studied children with autism spectrum disorder and reported abnormal MRI in 3.3% of 782 children [18]. To our knowledge, and after a literature search on 12 November 2026 (see Materials and Methods), no study has described MRI findings in Libyan children referred for developmental delay.

We therefore describe the brain MRI findings of 118 children with developmental delay scanned at a tertiary center in Misratah, Libya. We estimated the proportion with an abnormal MRI, described the pattern of findings, and examined whether the yield differs by sex, age, and gestational maturity.

Materials and methods

Design and setting

This retrospective cross-sectional study was carried out in the Department of Diagnostic Radiology at Misratah Medical Center, a tertiary hospital in Libya. It follows the Strengthening the Reporting of Observational Studies in Epidemiology (STROBE) reporting guideline [19]. Examinations performed between January 2019 and December 2023 were eligible.

Copyright *Author (s) 2026. Distributed under Creative Commons CC BY 4.0*
Received*: 17-09-2026 -* ***Accepted****: 15-11-2026 -* ***Published****: 24-11-2026*

Participants

Children were referred by the pediatric neurology unit for brain MRI because of a clinical diagnosis of developmental delay. Children were excluded if their clinical or imaging records were incomplete, the examination was non-diagnostic because of motion, they had a previously diagnosed post-traumatic structural brain lesion, or they had a known genetic syndrome unrelated to developmental delay. In all, 118 children were screened, and none were excluded on these criteria.

Clinical data

Age band, sex, gestational maturity (term or preterm), mode of delivery, birth history, antenatal history, family history, and the clinical notes were abstracted from the hospital record. Items that were not documented were coded as unknown and were not imputed.

MRI acquisition

All children were scanned on a 1.5 T Philips Achieva system (software release 5; Philips Healthcare, Best, The Netherlands). The standard pediatric brain protocol comprised axial and sagittal T1-weighted, axial and coronal T2-weighted, axial fluid-attenuated inversion recovery (FLAIR), and axial diffusion-weighted images. These sequences match the core of published pediatric brain protocols [20], which vary between institutions and with the clinical question [21]. Three-dimensional T1 or T2 sequences, and susceptibility-weighted images in a few children, were added at the radiologist's discretion; susceptibility-weighted imaging is sensitive to blood products and calcification [22]. A pediatric anesthesiologist supervised sedation or anesthesia when it was needed to obtain diagnostic images.

Image review and data extraction

Four board-certified radiologists (MD), each with at least 6 years of experience, reviewed each examination independently, with the clinical notes available, and entered the findings on a structured electronic form. They settled disagreements about interpretation by discussion. The form held these domains: brain anatomy and congenital malformation; gray matter; cerebellar malformation; phakomatosis; hydrocephalus (type and degree); myelination relative to age; white matter lesions (type and distribution); corpus callosum; basal ganglia; thalamus; dentate nucleus; brainstem; posterior fossa; the sequences that showed the finding best; additional findings; and a free-text conclusion.

Definitions

Abnormal MRI. A study was called abnormal when the structured form or the radiologist's conclusion recorded any finding other than a normal appearance. This covers an abnormal entry in any structured domain (brain anatomy, gray matter, cerebellar malformation, hydrocephalus, myelination other than appropriate for age, white matter lesion, corpus callosum, basal ganglia, thalamus, dentate nucleus, brainstem or posterior fossa) and any conclusion not reported as normal. We used this union because the form has no field for atrophy, volume loss, or encephalomalacia, and because benign enlargement of the subarachnoid spaces of infancy (BESSI) [23,24] was often written in the conclusion only. Non-specific findings were counted. One arachnoid cyst, noted only in the additional-findings field of a child whose conclusion was normal, was not counted. Two alternative definitions served as sensitivity analyses: a strict definition that excluded children whose only finding was a normal variant (BESSI or mega cisterna magna), and a structured-only definition that used the form fields and ignored the conclusion text.

Findings by domain. Each child was counted once per domain and could appear in several domains. Congenital malformation was defined as abnormal brain anatomy on the form, agenesis of the corpus callosum, Chiari malformation, Dandy–Walker malformation or variant, Joubert syndrome, vermian hypoplasia, gray matter heterotopia, polymicrogyria or schizencephaly (terms follow the current classification of malformations of cortical development) [25]. Volume loss, atrophy, and encephalomalacia were taken from the conclusion text.

Primary radiological category. Each child received one category, assigned in this order of precedence: congenital malformation; specific acquired insult named in the conclusion (kernicterus or congenital cytomegalovirus infection); suspected metabolic or dysmyelinating disease; ischemic or hypoxic white matter injury; hydrocephalus; hypomyelination or delayed myelination; non-specific white matter abnormality; volume loss, atrophy or focal encephalomalacia; deep gray nuclei signal abnormality; isolated thinning of the corpus callosum; normal variant only. The categories describe the imaging pattern. They are not etiological diagnoses and were not confirmed by laboratory, genetic, or follow-up data.

Age and maturity. Age had been recorded in bands (1–6 months, 7–12 months, 13–24 months, 3–5, 6–8, 9–11 and 12–14 years). We analyzed four groups (younger than 1 year, 1–2 years, 3–5 years, 6 years or older) and compared children younger than 3 years with children aged 3 years or older. The 3-year split was chosen after the data had been inspected and is post hoc. Maturity was term or preterm. It was documented for 45 children; the rest were analyzed as a separate "not documented" group.

Copyright *Author (s) 2026. Distributed under Creative Commons CC BY 4.0*
Received*: 17-09-2026 -* ***Accepted****: 15-11-2026 -* ***Published****: 24-11-2026*

Statistical analysis

We describe categorical data as counts and percentages with 95% Wilson confidence intervals (CI). Proportions were compared with Fisher's exact test, or with the chi-square test across the four age groups. A Cochran–Armitage test assessed the trend across age groups. Odds ratios (OR) came from 2×2 tables with Woolf confidence limits. A logistic regression model with abnormal MRI as the outcome and female sex and age younger than 3 years as covariates gave adjusted odds ratios. Maturity was not entered in the model because it was missing for 62% of children. Tests were two-sided with a significance level of 0.05. We made no adjustment for multiple comparisons, so the association analyses are exploratory. Analyses were run in Python 3.13 (pandas 3.0, SciPy 1.18, statsmodels 0.15). The analysis code was written with an artificial intelligence (AI) assistant (see Acknowledgments).

Literature search

PubMed was searched on 12 November 2026, without a language limit, for studies from Libya on brain MRI in children or on developmental delay and related disorders, and for recent studies (2024–2026) of MRI in developmental delay. Titles and abstracts were screened. No Libyan study of brain MRI in children with developmental delay was found; the only Libyan pediatric MRI series was in autism [18]. The other comparison studies came from the first author's dissertation. The comparison table in the Discussion lists the series that reported the proportion of children with an abnormal brain MRI; series in which most children had CT were not tabulated. No other database was searched, and the search was not systematic.

Ethics

The study used routinely collected clinical and imaging data. The Ethics and Scientific Research Committee of Misratah Medical Center approved the study, which followed the ethical principles of the Declaration of Helsinki. Individual consent was waived because the study was retrospective and used existing data. Patient names were not entered in the study database, and the analysis dataset uses study numbers in place of hospital file numbers.

Results

Study population

All 118 children screened were analyzed: 63 boys (53.4%) and 55 girls (46.6%). Ages ranged from 1 month to 14 years, and more than half of the children (65, 55.1%) were younger than 3 years (Table 1). No examinations were done in 2020 because the scanner was out of order (see Materials and Methods). Gestational maturity was documented for 45 children, 9 of whom (20.0%) were preterm. Birth, antenatal, delivery, and family history were documented for fewer than 11% of the children.

Table 1. Characteristics of the 118 children

Characteristic	n (%)
Sex	
Male	63 (53.4)
Female	55 (46.6)
Age	
1–6 months	8 (6.8)
7–12 months	20 (16.9)
13–24 months	37 (31.4)
3–5 years	23 (19.5)
6–8 years	17 (14.4)
9–11 years	11 (9.3)
12–14 years	2 (1.7)
Subtotal: younger than 3 years	*65 (55.1)*
Gestational maturity	
Term	36 (30.5)
Preterm	9 (7.6)
Not documented	73 (61.9)
Birth history	
NICU admission	7 (5.9)
Birth asphyxia	2 (1.7)
Uneventful	3 (2.5)
Not documented	106 (89.8)
Antenatal history	

Copyright *Author (s) 2026. Distributed under Creative Commons CC BY 4.0*
Received*: 17-09-2026 -* ***Accepted****: 15-11-2026 -* ***Published****: 24-11-2026*

Characteristic	n (%)
Positive	3 (2.5)
Negative	5 (4.2)
Not documented	110 (93.2)
Mode of delivery	
Vaginal	3 (2.5)
Cesarean	2 (1.7)
Not documented	113 (95.8)
Family history	
Positive or consanguinity	2 (1.7)
Negative	3 (2.5)
Not documented	113 (95.8)
Registration year	
2019	23 (19.5)
2021	39 (33.1)
2022	20 (16.9)
2023	36 (30.5)

Percentages are of all 118 children. Subtotal: the sum of the first three age bands (1–6, 7–12 and 13–24 months), not a separate group. NICU, neonatal intensive care unit.

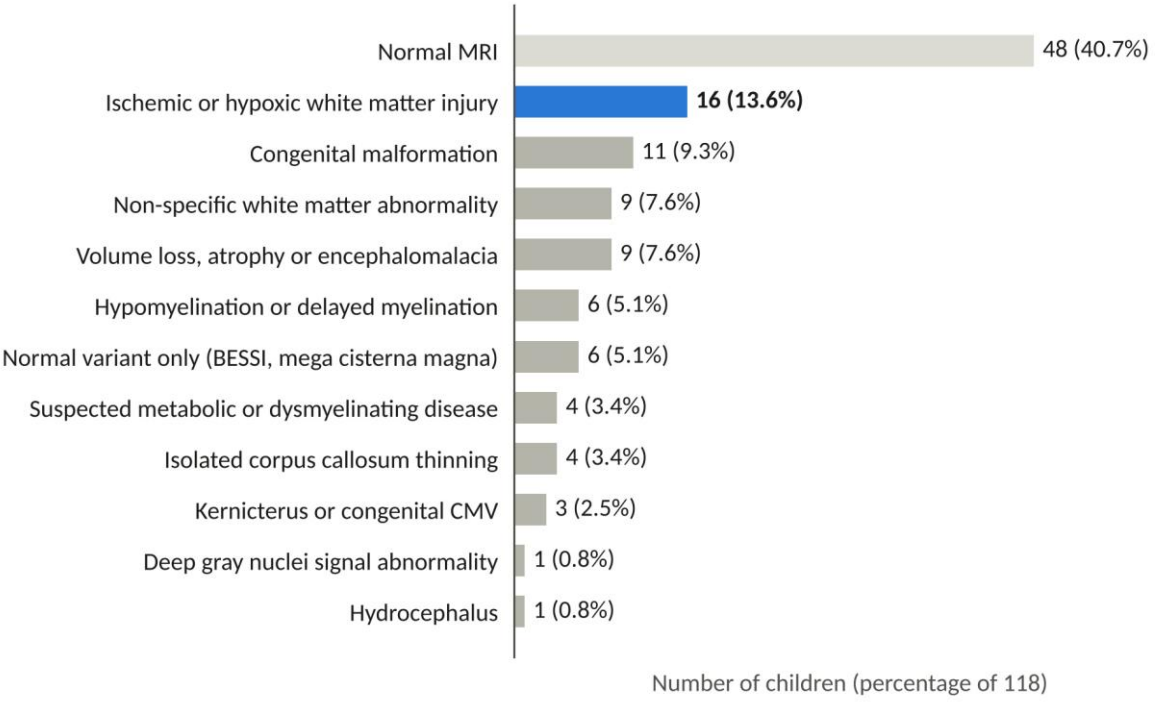

Figure 1. Primary radiological category in 118 children. Each child is counted once, under the first matching category in the order given in Materials and Methods. BESSI, benign enlargement of the subarachnoid spaces of infancy; CMV, cytomegalovirus.

Overall yield

MRI was abnormal in 70 of 118 children (59.3%; 95% CI 50.3–67.8; Table 2). The yield was 54.2% under the strict definition, which removed the six children whose only finding was a normal variant, and 53.4% with form fields alone. The seven studies that were abnormal on the conclusion text alone showed volume loss, atrophy, or encephalomalacia (six) or BESSI (one).

Spectrum of findings

White matter lesions were the most frequent finding (34 children, 28.8%; Table 2), and 28 of the 34 involved the periventricular white matter. The corpus callosum was abnormal in 20 children (16.9%), thin in 15 and absent in 5. Volume loss, atrophy, or encephalomalacia was described in 18 children (15.3%) and a myelination abnormality in 13 (11.0%).

Copyright *Author (s) 2026. Distributed under Creative Commons CC BY 4.0*
Received*: 17-09-2026 -* ***Accepted****: 15-11-2026 -* ***Published****: 24-11-2026*

Congenital malformations were present in 11 children (9.3%), most often agenesis of the corpus callosum (5). The other findings are listed in Table 2. No child had a brainstem abnormality.

Table 2. Brain MRI findings in 118 children

Finding	n	% (95% CI)	Details
Abnormal MRI, primary definition	70	59.3 (50.3–67.8)	Form or conclusion
Abnormal MRI, strict definition	64	54.2 (45.3–63.0)	Normal variants alone excluded
Abnormal MRI, form fields only	63	53.4 (44.4–62.1)	Conclusion text ignored
Normal variant only	6	5.1 (2.4–10.7)	BESSI or mega cisterna magna
White matter lesion	34	28.8 (21.4–37.6)	Ischemic or anoxic 16; metabolic 2; not otherwise specified 16; periventricular involvement 28
Corpus callosum abnormality	20	16.9 (11.2–24.7)	Thinning 15; agenesis 5
Volume loss, atrophy or encephalomalacia	18	15.3 (9.9–22.8)	From the conclusion text
Myelination abnormality	13	11.0 (6.6–17.9)	Hypomyelination 9; dysmyelination 3; both 1
Congenital malformation	11	9.3 (5.3–15.9)	Corpus callosum agenesis 5; Chiari malformation 2; heterotopia 2; Dandy–Walker malformation 1; Dandy–Walker variant 1; Joubert syndrome 1; polymicrogyria 1; schizencephaly 1; vermian hypoplasia 3
BESSI	10	8.5 (4.7–14.9)	On the form 3; added from the conclusion text 7
Deep gray nuclei	9	7.6 (4.1–13.9)	Basal ganglia 8; thalamus 3; dentate nucleus 1
Hydrocephalus	8	6.8 (3.5–12.8)	Communicating 4; non-communicating 4
Posterior fossa abnormality	7	5.9 (2.9–11.7)	Chiari malformation 2; mega cisterna magna 2; Dandy–Walker malformation 1; Dandy–Walker variant 1; Joubert syndrome 1
Gray matter abnormality	4	3.4 (1.3–8.4)	Heterotopia 2; polymicrogyria 1; cortical laminar necrosis 1
Cerebellar vermian hypoplasia	3	2.5 (0.9–7.2)	
Brainstem abnormality	0	0 (0–3.2)	

A child can appear in more than one row below the first four. CI, Wilson 95% confidence interval. BESSI, benign enlargement of the subarachnoid spaces of infancy.

Primary radiological category

Forty-eight children (40.7%) had a normal examination. Among the abnormal studies, ischemic or hypoxic white matter injury was the commonest primary category (16 children; 13.6% of all children and 22.9% of abnormal studies), followed by congenital malformation (11), non-specific white matter abnormality (9) and volume loss, atrophy or focal encephalomalacia (9). The remaining categories are shown in Figure 1.

Sex, age and maturity

Abnormal MRI was more frequent in girls than in boys (70.9% vs 49.2%; p = 0.024), and girls had the higher yield in every age group (Table 3, Figure 2). Yield fell with age (trend p = 0.014), and children younger than 3 years were abnormal more often than children aged 3 years or older (69.2% vs 47.2%; p = 0.023). When both factors were entered in one model, female sex (adjusted OR 3.08, 95% CI 1.36–6.95) and age younger than 3 years (adjusted OR 3.08, 95% CI 1.38–6.89) each kept their association (Table 4). All nine preterm children had an abnormal MRI, compared with 22 of 36 term children (61.1%; p = 0.040; Table 3). Seven of the nine preterm children had a white matter lesion, compared with 10 of 36 term children (27.8%; p = 0.017). Malformations were more frequent in girls (8 of the 11). Without the children who had malformations, the sex difference narrowed to 31 of 47 girls (66.0%) against 28 of 60 boys (46.7%; p = 0.053).

Table 3. Abnormal MRI by sex, age and gestational maturity

Factor	Group	Childre n	Abnormal, primary n (%)	p	Abnormal, strict n (%)	p
Sex	Female	55	39 (70.9)	0.024	36 (65.5)	0.027
	Male	63	31 (49.2)		28 (44.4)	
Age group	Younger than 1 year	28	19 (67.9)	0.060 (trend 0.014)	16 (57.1)	0.23 (trend 0.10)
	1–2 years	37	26 (70.3)		24 (64.9)	

Copyright *Author (s) 2026. Distributed under Creative Commons CC BY 4.0*
***Received**: 17-09-2026 - **Accepted**: 15-11-2026 - **Published**: 24-11-2026*

Factor	Group	Childre n	Abnormal, primary n (%)	p	Abnormal, strict n (%)	p
	3–5 years	23	13 (56.5)		12 (52.2)	
	6 years or older	30	12 (40.0)		12 (40.0)	
Age split	Younger than 3 years	65	45 (69.2)	0.023	40 (61.5)	0.096
	3 years or older	53	25 (47.2)		24 (45.3)	
Maturity	Preterm	9	9 (100)	0.040	9 (100)	0.017
	Term	36	22 (61.1)		20 (55.6)	
	Not documented	73	39 (53.4)		35 (47.9)	

P-values come from Fisher's exact test (sex, age split, preterm against term) and from the chi-square test across the four age groups, with the Cochran–Armitage trend test in brackets. We excluded children with undocumented maturity from the maturity test. Primary definition: any abnormal finding on the form or in the conclusion; strict definition: normal variants alone excluded.

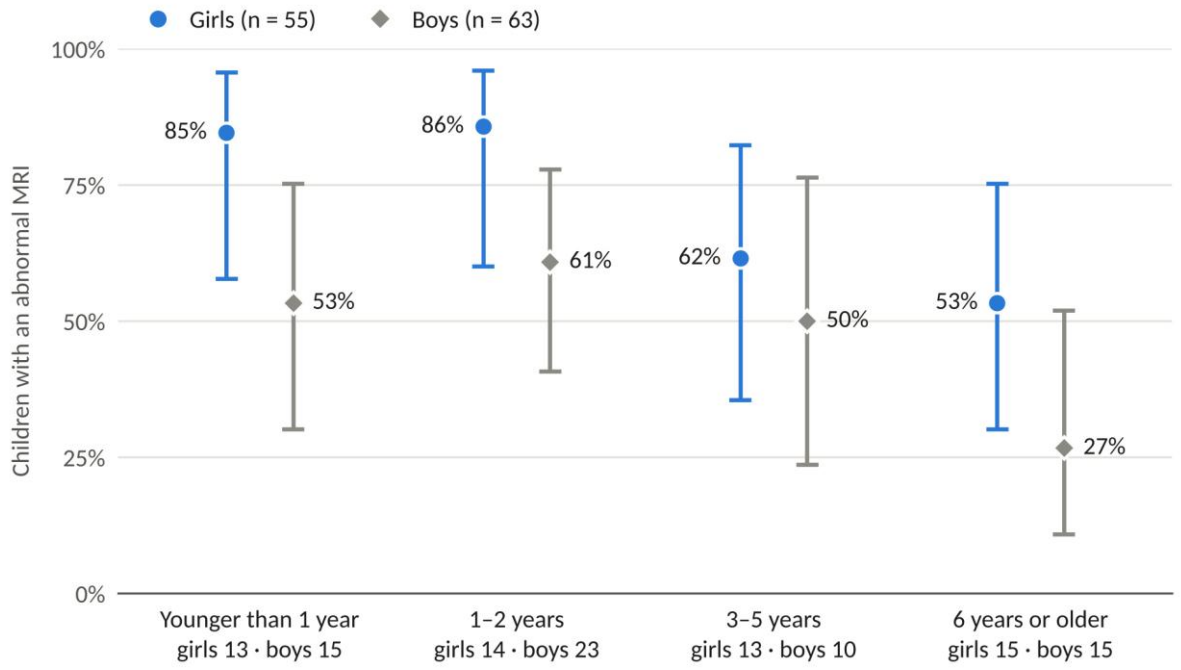

Figure 2. Share of children with an abnormal MRI (primary definition) by age group and sex. Dots show the percentage and whiskers show Wilson 95% confidence intervals. The number of girls and boys in each group is printed under the age label. Overall rates and tests are in Table 3.

Sensitivity analyses

Under the strict definition, the sex difference persisted (p = 0.027), but the age difference weakened (p = 0.096; Tables 3 and 4), and the preterm association strengthened (all nine against 20 of 36 term children; p = 0.017). Using form fields alone, the sex difference held (p = 0.017), the age difference was borderline (61.5% vs 43.4%; p = 0.064), and the preterm association disappeared (7 of 9 vs 22 of 36; p = 0.456). Excluding the two children aged 12–14 years left the results unchanged (yield 59.5%; sex p = 0.022; age p = 0.022). Yield by registration year was 52.2% in 2019, 56.4% in 2021, 65.0% in 2022, and 63.9% in 2023, without a significant trend (p = 0.31).

Imaging examples

Figures 3 to 5 show examples of the findings in Table 2. Figure 3 shows white matter lesions and myelination abnormalities. Figure 4 shows corpus callosum and deep gray nuclei abnormalities, BESSI, and hydrocephalus. Figure 5 shows gray matter and posterior fossa abnormalities. We did not image generalized atrophy or encephalomalacia, schizencephaly, Dandy–Walker malformation, cortical laminar necrosis, or thalamic and dentate nucleus changes, and no child had a brainstem abnormality.

Copyright *Author (s) 2026. Distributed under Creative Commons CC BY 4.0*
***Received**: 17-09-2026 - **Accepted**: 15-11-2026 - **Published**: 24-11-2026*

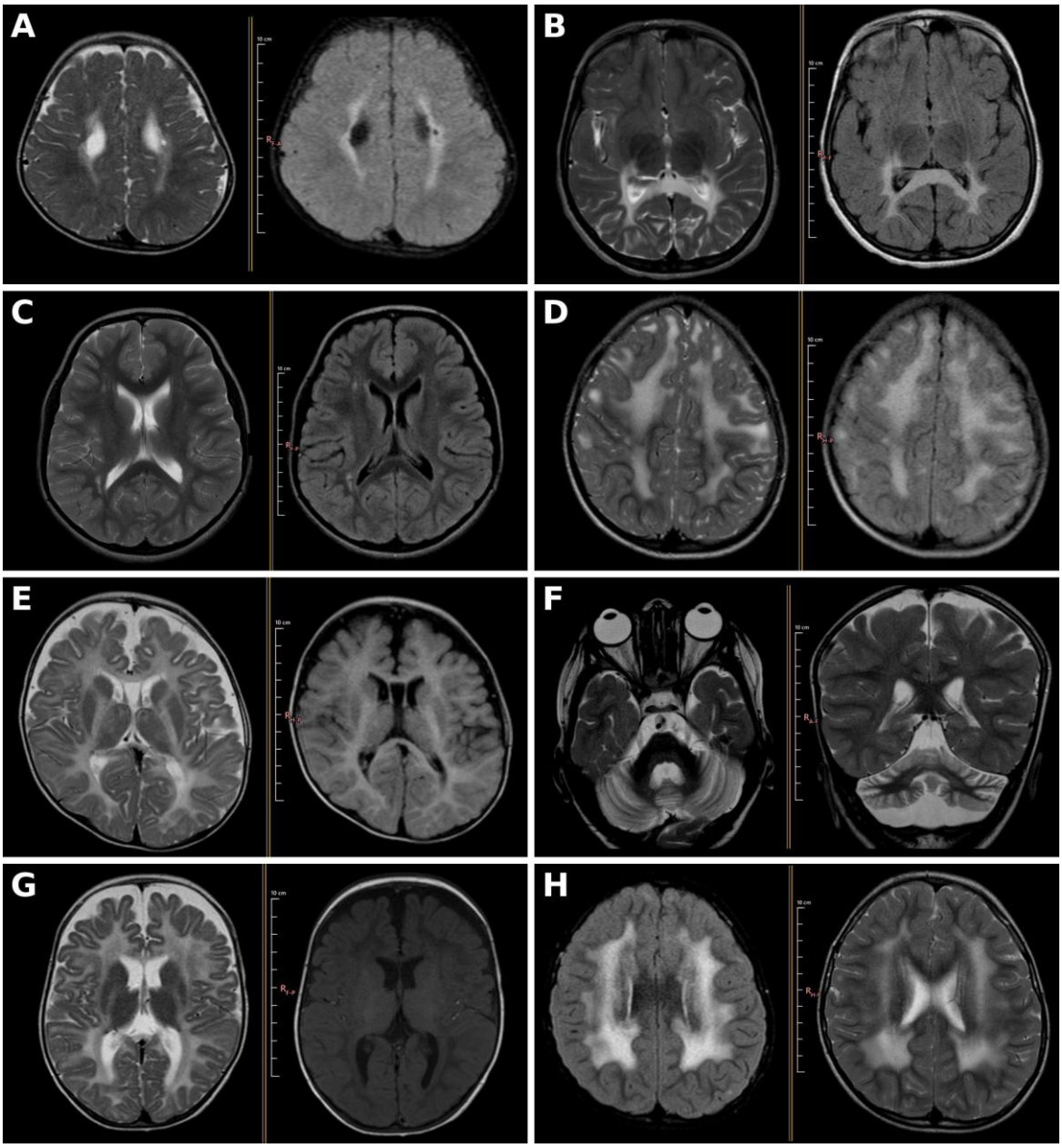

Figure 3. White matter lesions and myelination abnormalities on MRI. In each panel the planes or sequences are listed from left to right. (A) Ischemic injury: axial T2-weighted and FLAIR images show high signal in the periventricular white matter, consistent with an ischemic insult. (B) Metabolic disease: axial T2-weighted and FLAIR images show periventricular high signal, mainly around the occipital horns and extending to the splenium of the corpus callosum, suggesting leukodystrophy with metabolic encephalopathy. (C) Non-specific changes: axial T2-weighted and FLAIR images show periventricular and subcortical high signal in the frontoparietal region, in keeping with non-specific white matter changes. (D) Subcortical and centrum semiovale involvement: axial T2-weighted and FLAIR images show high signal in the subcortical white matter and centrum semiovale. (E) Diffuse involvement: axial T2-weighted and FLAIR images show diffuse white matter high signal. (F) Cerebellar involvement: axial and coronal T2-weighted images show hyperintense cerebellar parenchyma. (G) Hypomyelination: axial T2-weighted and T1-weighted images show T1 and T2 prolongation of the subcortical and deep white matter, consistent with a hypomyelinating disorder. (H) Dysmyelination: axial FLAIR and T2-weighted images show high signal in the periventricular white matter, consistent with a dysmyelinating disorder. Text on the screen captures (dates, times, ages, sex, series and frame numbers) and viewer icons was blacked out; no other change was made to the image content. FLAIR, fluid-attenuated inversion recovery.

Copyright *Author (s) 2026. Distributed under Creative Commons CC BY 4.0*
Received*: 17-09-2026 -* ***Accepted****: 15-11-2026 -* ***Published****: 24-11-2026*

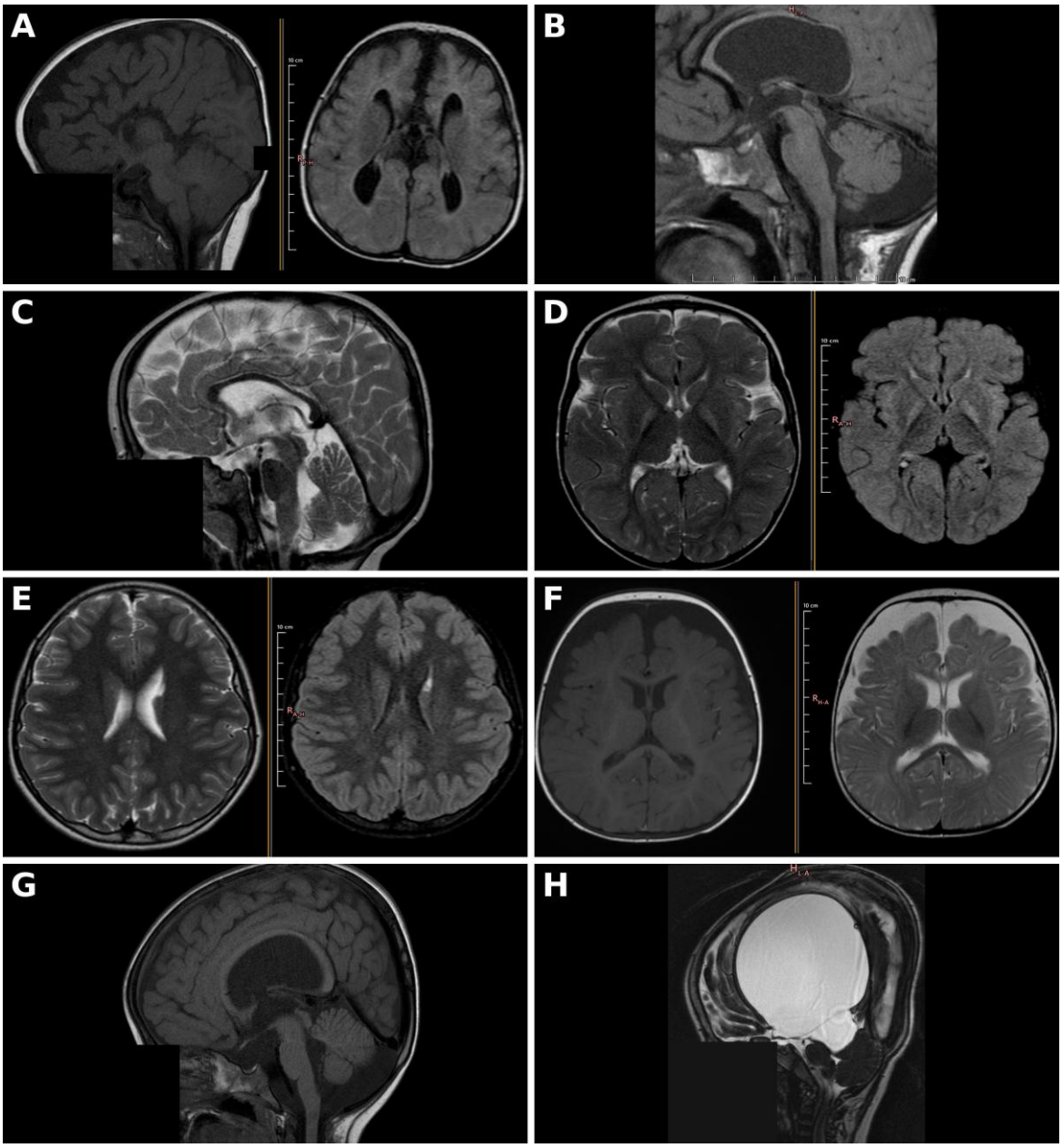

Figure 4. Corpus callosum, deep gray nuclei and cerebrospinal fluid spaces on MRI. In each panel the planes or sequences are listed from left to right. (A) Corpus callosum agenesis: sagittal and axial T1-weighted images show agenesis of the corpus callosum. (B) Corpus callosum dysgenesis: sagittal T1-weighted image shows dysgenesis of the corpus callosum. (C) Corpus callosum thinning: sagittal T2-weighted image shows a thin corpus callosum. (D) Globus pallidus: axial T2-weighted and FLAIR images show high signal in both globi pallidi. (E) Caudate nucleus: axial T2-weighted and FLAIR images show high signal and volume loss in the left caudate body. (F) BESSI, a normal variant: axial T1-weighted and T2-weighted images show widening of the bifrontal and anterior interhemispheric CSF spaces. (G) Communicating hydrocephalus: sagittal T1-weighted image shows mild communicating hydrocephalus. (H) Non-communicating hydrocephalus: sagittal CSF-DRIVE image shows severe non-communicating hydrocephalus. Text on the screen captures (dates, times, ages, sex, series and frame numbers) and viewer icons was blacked out, and the face below the skull base was blacked out in the sagittal images in panels A, C, G and H; no other change was made to the image content. BESSI, benign enlargement of the subarachnoid spaces of infancy; CSF, cerebrospinal fluid; DRIVE, driven equilibrium; FLAIR, fluid-attenuated inversion recovery.

Copyright *Author (s) 2026. Distributed under Creative Commons CC BY 4.0*
***Received**: 17-09-2026 - **Accepted**: 15-11-2026 - **Published**: 24-11-2026*

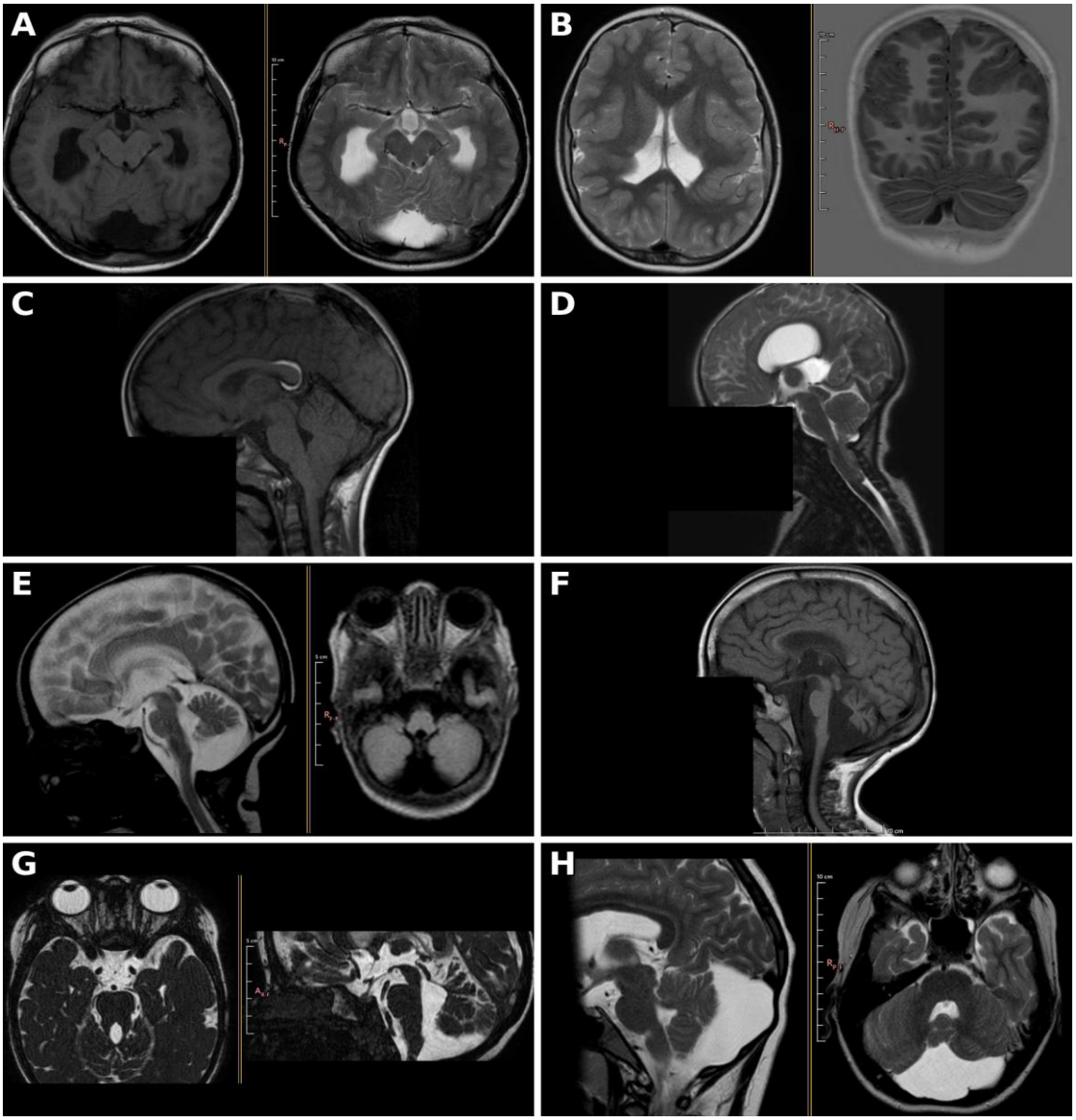

Figure 5. Gray matter and posterior fossa abnormalities on MRI. In each panel the planes or sequences are listed from left to right. (A) Subependymal heterotopia: axial T1-weighted and T2-weighted images show subependymal heterotopia at the occipital horn. (B) Polymicrogyria: axial T2-weighted and coronal T1-weighted images show polymicrogyria, most evident around the Sylvian fissures. (C) Chiari I malformation: sagittal T1-weighted image shows a Chiari I malformation with a pericallosal lipoma. (D) Chiari II malformation: sagittal T2-weighted image shows a Chiari II malformation; the image is cropped to the head and neck. (E) Dandy–Walker variant: sagittal T2-weighted and axial FLAIR images are consistent with a Dandy–Walker variant. (F) Cerebellar vermian hypoplasia: sagittal T1-weighted image shows inferior vermian hypoplasia. (G) Joubert syndrome: axial and sagittal B-FFE images are consistent with Joubert syndrome. (H) Mega cisterna magna, a normal variant: sagittal and axial T2-weighted images are consistent with a mega cisterna magna. Text on the screen captures (dates, times, ages, sex, series and frame numbers) and viewer icons was blacked out, and the face below the skull base was blacked out in the sagittal images in panels C, D and F; no other change was made to the image content. B-FFE, balanced fast field echo; FLAIR, fluid-attenuated inversion recovery.

Table 4. Odds of an abnormal MRI, crude and adjusted

Definition	Factor	Crude OR (95% CI)	Adjusted OR (95% CI)	p (adjusted)
Primary	Female vs male	2.52 (1.17–5.40)	3.08 (1.36–6.95)	0.007
Primary	Younger than 3 years vs 3 years or older	2.52 (1.19–5.36)	3.08 (1.38–6.89)	0.006
Strict	Female vs male	2.37 (1.12–4.99)	2.69 (1.24–5.85)	0.012
Strict	Younger than 3 years vs 3 years or older	1.93 (0.93–4.04)	2.26 (1.04–4.90)	0.039

Adjusted odds ratios come from one logistic regression model per definition, with sex and age group (younger than 3 years vs 3 years or older) entered together. OR, odds ratio. The adjusted odds ratios for sex and age in the primary model are almost equal by chance (3.078 and 3.077 before rounding).

Copyright *Author (s) 2026. Distributed under Creative Commons CC BY 4.0*
Received*: 17-09-2026 -* ***Accepted****: 15-11-2026 -* ***Published****: 24-11-2026*

Table 5. Comparison with published series, ordered by increasing proportion with abnormal MRI

Study	Country	Design	n	Age	Abnormal MRI	Leading findings
Present study	Libya	Retrospective, single center	118	1 mo–14 y	59.3% (54.2% strict)	White matter lesion 28.8%; ischemic or hypoxic white matter injury 13.6%; corpus callosum abnormality 16.9%
Habibullah et al., 2020 [7]	Saudi Arabia, Dammam	Retrospective	170	Not stated †	54.7%	Ventricles and white matter, especially the corpus callosum, most often affected
Momen et al., 2011 [9]	Iran	Record review, 1997–2009	580	2 mo–15 y	58.6%	Neurovascular disease or trauma 37.6%; metabolic or neurodegenerative 7.2%; congenital anomalies 6.7%
Chaudhary et al., 2021 [10]	India, Wardha	Cross-sectional, descriptive	104	3 mo–15 y	60.6%	Hypoxic-ischemic injury 49.2% of abnormal scans; ventricles 47.1%, corpus callosum 41.3%, white matter 28.8%
Elanchezhian and Kalaivani, 2020 [14]	India, Salem	Prospective, observational	42	6 mo–12 y	61.9%	Hypoxic-ischemic changes, white matter disorders and atrophic changes 6 children each (23.1% of abnormal scans each)
Ali et al., 2015 [11]	India, Hyderabad	Prospective, observational	81	3 mo–12 y	68%	Traumatic or neurovascular 31%; congenital or developmental 17%; metabolic or degenerative 10%
Alamri et al., 2021 [8]	Saudi Arabia	Retrospective chart review	218	Mean 37.9 mo	70%	White matter 68% of abnormal scans; corpus callosum 50%; hippocampus 33%
Das et al., 2024 [12]	India, Davangere	Cross-sectional	110	3 mo–5 y	72.8%‡	Hypoxic-ischemic insult the most common cause
Balcha et al., 2022 [16]	Ethiopia	Retrospective, descriptive	164	5 mo–13 y	73.2%	Neurovascular insults 45.7% (hypoxic-ischemic encephalopathy 42.1%); congenital anomalies 12.2%
Randhawa et al., 2022 [13]	India	Prospective, cross-sectional	60	3 mo–12 y	80%	Perinatal hypoxic insult 36.7%; structural abnormalities 20%; non-specific findings 18.3%
Abd Elghaffar et al., 2020 [17]	Egypt	Prospective, descriptive	65	3 mo–18 y	82%	Metabolic or degenerative disorders 41.5% and congenital anomalies 26.2% of abnormal findings
Dittakavi et al., 2023 [15]	India, Narketpally	Retrospective, observational	40	6 mo–12 y	87.5%	Metabolic or degenerative disorders 40%, congenital malformations 37.5%; white matter involved in 52.5%§
Murias et al., 2017 [4]	29 studies	Systematic review	2,299	Birth–18 y	38% (range 0–98%)¶	Etiological diagnosis 7.9%

n, number of children; mo, months; y, years. Percentages of leading findings refer to all children unless stated. Definitions of an abnormal MRI differ between studies, so the percentages are not strictly comparable.
The present study is shown first and the systematic review last.
† Habibullah et al.: the age range is not given in the abstract.
‡ Das et al.: calculated from the 27.2% reported as normal.
§ Dittakavi et al.: the reported categories add up to the abnormal rate, so we read their percentages as shares of all children.
¶ Murias et al.: systematic review of children with isolated global developmental delay or intellectual disability; the range is across its 29 studies.

Discussion

In this retrospective series of 118 children referred with developmental delay to a Libyan tertiary center, brain MRI was abnormal in 59.3% (54.2% when isolated normal variants are set aside). White matter lesions were the commonest finding, and ischemic or hypoxic white matter injury was the commonest specific pattern. The yield was higher in girls, in children younger than 3 years, and in the nine preterm children.

Copyright *Author (s) 2026. Distributed under Creative Commons CC BY 4.0*
Received*: 17-09-2026 -* ***Accepted****: 15-11-2026 -* ***Published****: 24-11-2026*

Yield compared with other series

A systematic review of children with isolated global developmental delay or intellectual disability puts the proportion with abnormal MRI at 38% (study rates 0% to 98%) [4], and an American Academy of Pediatrics report gives about 30% [3]. Our figure is higher. It is close to the yields of an Iranian record review (58.6%) [9], a Saudi series from Dammam (54.7%) [7], and two Indian series (60.6% and 61.9%) [10,14], and lower than the other seven series, which report 68% to 87.5% [8,11–13,15–17] (Table 5). A hospital series from Yaoundé, Cameroon, in which most children had CT and not MRI (85.1% against 14.9%), found abnormal imaging in 78.7% of 94 children [26]. Referral thresholds, age range, the mix of global and single-domain delay, and the handling of non-specific findings probably explain much of this spread. The one Libyan neuroimaging series we found studied children with autism spectrum disorder and reported abnormal MRI in 3.3% of 782 children [18]; its population and question differ from ours, so it is not a benchmark. Our children were referred for MRI, and we have no denominator of all children with delay, so 59% is not the prevalence of MRI abnormality among children with delay in Libya.

Spectrum of findings

Perinatal hypoxic–ischemic injury leads the acquired findings in most series from low- and middle-income settings. It accounted for 42.1% of children in Ethiopia [16], 36.7% in one Indian series [13], and 42% in another [27], and for 49.2% of the abnormal scans in a third [10]. In a fourth Indian series, it shared the lead with white matter disorders and atrophic changes (23.1% of the abnormal scans each) [14]. Neurovascular disease or trauma accounted for 37.6% in Iran [9]. Our 13.6% for ischemic or hypoxic white matter injury is lower. The form offered no field for hypoxic-ischemic encephalopathy as a diagnosis, and 16 further white matter lesions were typed as not otherwise specified. Their periventricular predominance (28 of 34 lesions overall) fits an ischemic or prematurity-related origin. In preterm infants, periventricular white matter injury often comes with damage to the thalamus, basal ganglia, cortex, cerebellum, and brainstem, a picture called encephalopathy of prematurity [28].

White matter was involved in 48.6% of our abnormal studies and the corpus callosum in 28.6%, compared with 68% and 50% in the Saudi series [8]. White matter was also commonly involved in the Narketpally series (52.5% of children) [15]. Callosal thinning was commoner than agenesis (15 vs 5) and coincided with volume loss or atrophy in seven of the 20 children. Callosal anomalies are an important indicator of further brain anomalies [29], so an abnormal corpus callosum is a reason to review the whole scan. Myelination was abnormal in 11.0%, and four children (5.7% of abnormal studies) fell into the suspected metabolic or dysmyelinating category, far fewer than the 41.5% of abnormal findings reported from Egypt [17]. We cannot tell whether that gap reflects case mix or under-recognition. Our protocol did not include spectroscopy, the form had no field for metabolic patterns, and myelination is hard to judge in the first two years of life, when it matures fast, and its signal on T1-weighted, T2-weighted, and FLAIR images changes at different ages [30–34]. The ages at which myelination patterns appear differ between normal and developmentally delayed infants [35]. Congenital malformations (9.3%) fall within the 6.7% to 20% reported for congenital or structural anomalies in the Iranian, Ethiopian and Indian series [9,13,16]. Callosal agenesis was the most common malformation (5 of 11). Cortical malformations were uncommon (heterotopia 2, polymicrogyria 1, schizencephaly 1) and are named as in the current classification [25].

Sex

The excess of abnormal MRI in girls (70.9% vs 49.2%) was the most consistent association. It appeared in every age group, strengthened on adjustment for age (adjusted odds ratio 3.08), and held under all three definitions. It narrowed to a borderline difference ($p = 0.053$) when the 11 children with malformations were removed; 8 of them were girls. An Indian series found no link between sex and MRI result ($p = 0.364$) [13]. One explanation is that boys with delay are referred for MRI at a lower threshold, which dilutes the yield in boys. Autism, which is more frequent in boys [36], is one example: only 3.3% of the Libyan children with autism in one series had an abnormal MRI [18]. Another comes from genetics: girls with neurodevelopmental disorders carry more rare damaging variants than boys, consistent with a female protective effect [37], so girls who reach the threshold for delay may more often have a structural cause. Sex differences in brain development themselves have both hormonal and genetic origins [38]. The comparison was not planned, and our data cannot separate these explanations, so the finding needs replication.

Age and prematurity

Yield fell with age (69.2% in children younger than 3 years, 47.2% in those aged 3 years or older; trend $p = 0.014$), but the difference was not robust. It weakened under the strict definition ($p = 0.096$) and with form fields alone ($p = 0.064$). The Indian series found no difference by age [13]. Severe perinatal injury and malformation tend to present early, whereas children aged 3 years or older may be referred for milder, single-domain delay. We lacked the clinical data to test this. Brain and white matter maturation is fastest in the first years of life [39,40], so what counts as a normal scan changes with age, and readers may judge the youngest children differently. All nine preterm children had an abnormal MRI and seven had a white matter lesion, which fits the prematurity literature [28,41]. The group is small, the association with any abnormality disappeared when only form fields were used, and maturity may have been recorded mainly for children with perinatal problems.

Copyright *Author (s) 2026. Distributed under Creative Commons CC BY 4.0*
Received*: 17-09-2026 -* ***Accepted****: 15-11-2026 -* ***Published****: 24-11-2026*

Implications

Guidance differs on whom to image. The 2003 American Academy of Neurology parameter recommends neuroimaging in global developmental delay, with MRI preferred, particularly when the examination is abnormal [2]. The American Academy of Pediatrics report advises MRI chiefly when head size or the neurological examination is abnormal [3]. A systematic review found the evidence too limited for firm recommendations and suggested MRI for children who remain undiagnosed after a thorough clinical evaluation [4]. A 2026 review also questions routine MRI in mild intellectual disability without other clinical signs and favors imaging guided by the child's phenotype and developmental course [42]. Abnormal findings were common in our referred children (54% to 59%), but an abnormal scan is not a diagnosis: the systematic review found an etiological diagnosis in only 7.9% [4], and we could not estimate that figure because we had no laboratory, genetic, or follow-up data. In a Slovenian outpatient series of 123 children with unexplained global developmental delay, MRI was critical for the diagnosis in only 1 of 81 children (1.2%), while genetic testing gave a diagnosis in 47.1% [43]. This paper therefore cannot say which children need MRI, because we did not analyze the clinical findings that guidelines use, and we do not know whether results changed diagnosis or care.

Newer MRI techniques [44], such as phase-contrast cerebrospinal fluid (CSF) flow imaging [45] and MR spectroscopy, were not part of the standard protocol; they might add information in hydrocephalus and in suspected metabolic disease, respectively. Many young children need sedation or general anesthesia for MRI, so a repeat scan is a burden [21]. Fast, motion-compensated protocols designed for awake children [46] may help to avoid sedation and repeat scans. Our audit also points to fixes for the report form: add atrophy and encephalomalacia, code BESSI consistently, and make maturity and perinatal history required fields, since they were missing for 62% to 96% of children.

Strengths and limitations

Strengths are a structured report form, reading by four radiologists, sensitivity analyses under three outcome definitions, and a data audit that shows how the definition of an abnormal scan shapes the result. The study also has limitations. It is retrospective and single-center, and the children were referred for MRI, so selection bias is likely, and the findings may not apply to other Libyan centers or to children who are not referred for MRI. The readers were not blinded to the clinical notes, which sit on the same form, and they settled disagreements by discussion; the database holds only the final reading, so inter-reader agreement could not be measured. The form lacked fields for atrophy, volume loss, and encephalomalacia and recorded BESSI inconsistently; we recovered these findings from the conclusion text, which may have missed some. The radiological categories were assigned by fixed rules applied to the reports, and no laboratory, genetic, or follow-up data confirmed them. Maturity, birth history, and family history were missing for most children, so we could not adjust for perinatal factors. Age was recorded in bands; the 3-year split was post hoc, and no correction was made for multiple testing (see Materials and Methods), so the associations are hypotheses. The relation of MRI findings to clinical presentation was not analyzed here. Because the literature search was not systematic (see Materials and Methods), Table 5 is a selection of published series, and some studies may have been missed.

Conclusion

About three in five children referred for developmental delay to this Libyan center had an abnormal brain MRI, most often with a white matter lesion. Girls and children younger than 3 years had the higher yield, although the age effect depended on how an abnormal scan was defined. Prospective, multicenter studies that record perinatal and clinical data are needed to confirm these associations and to show which children gain most from MRI.

Declarations

Abbreviations

AI, artificial intelligence; BESSI, benign enlargement of the subarachnoid spaces of infancy; CI, confidence interval; CSF, cerebrospinal fluid; CT, computed tomography; FLAIR, fluid-attenuated inversion recovery; MRI, magnetic resonance imaging; NICU, neonatal intensive care unit; OR, odds ratio; STROBE, Strengthening the Reporting of Observational Studies in Epidemiology.

Ethics approval and consent to participate

The Ethics and Scientific Research Committee of Misratah Medical Center approved the study, which followed the ethical principles of the Declaration of Helsinki. Individual consent was waived because the study was retrospective.

Consent for publication

Individual consent was waived (see Ethics approval and consent to participate). The MRI images in Figures 3 to 5 are anonymized: dates, times, ages, sex, series and frame numbers and other on-screen text were removed, and the face was blacked out in sagittal images where it was visible.

Availability of data and materials

The coded dataset, in which hospital file numbers are replaced by study numbers, and the analysis scripts are available from the corresponding author upon reasonable request.

Copyright *Author (s) 2026. Distributed under Creative Commons CC BY 4.0*
Received*: 17-09-2026 -* ***Accepted****: 15-11-2026 -* ***Published****: 24-11-2026*

Conflicts of interest
Fatma Abusaa, Yousef Elshrimi, Fatima Alajtel and Suad Endish each declare that they have no conflicts of interest.

Funding
The study received no external funding, so there is no funder, and there are no grant numbers.

Authors' contributions
Fatma Abusaa: Investigation, Data curation, Writing – review & editing. Yousef Elshrimi: Conceptualization, Methodology (study and dataset design), Supervision, Writing – review & editing. Fatima Alajtel and Suad Endish: Investigation (data collection and interpretation), Writing – review & editing. All authors read and approved the final manuscript and agree to be accountable for all aspects of the work.

Acknowledgments
This paper is based on the first author's dissertation in radiology (Libyan Board of Health Specialties, January 2024), which the senior author supervised. The images in Figures 3 to 5 are taken from the dissertation. We thank Hana M. Alswaie and Amina S. Bengishir for their help with data collection and image interpretation.

Use of AI tools
In November 2026, under the direction of the authors, Claude Sonnet 5.5 (Anthropic), an AI assistant, cleaned the data, wrote the code and ran the statistical analysis, carried out the literature search, drew Figures 1 and 2, prepared the image panels of Figures 3 to 5, and wrote the first draft of this manuscript. Claude is not an author. The authors checked the data, the analysis output, and the text and take responsibility for the content.

References
[1] Olusanya BO, Davis AC, Wertlieb D, Boo NY, Nair MKC, Halpern R, et al. Developmental disabilities among children younger than 5 years in 195 countries and territories, 1990-2016: a systematic analysis for the Global Burden of Disease Study 2016. Lancet Glob Health. 2018 Oct;6(10):e1100-e1121. doi: 10.1016/S2214-109X(18)30309-7.
[2] Shevell M, Ashwal S, Donley D, Flint J, Gingold M, Hirtz D, et al. Practice parameter: evaluation of the child with global developmental delay: report of the Quality Standards Subcommittee of the American Academy of Neurology and the Practice Committee of the Child Neurology Society. Neurology. 2003 Feb 11;60(3):367-80. doi: 10.1212/01.wnl.0000031431.81555.16.
[3] Moeschler JB, Shevell M; Committee on Genetics. Comprehensive evaluation of the child with intellectual disability or global developmental delays. Pediatrics. 2014 Sep;134(3):e903-18. doi: 10.1542/peds.2014-1839.
[4] Murias K, Moir A, Myers KA, Liu I, Wei XC. Systematic review of MRI findings in children with developmental delay or cognitive impairment. Brain Dev. 2017 Sep;39(8):644-655. doi: 10.1016/j.braindev.2017.04.006.
[5] Merino Elia A, Coghill J. A practical guide to assessing and investigating developmental delay. Paediatr Child Health. 2021 Sep;31(9):335-339.
[6] Williams HJ. Imaging the child with developmental delay. Imaging. 2004;16(2):174-185.
[7] Habibullah H, Albaradie R, Bashir S. MRI evaluation of global developmental delay: a retrospective study. Dubai Med J. 2020;3(1):1-4. doi: 10.1159/000506900.
[8] Alamri A, Aljadhai YI, Alrashed A, Alfheed B, Abdelmoaty R, Alenazi S, et al. Identifying clinical clues in children with global developmental delay/intellectual disability with abnormal brain magnetic resonance imaging (MRI). J Child Neurol. 2021 May;36(6):432-439. doi: 10.1177/0883073820977330.
[9] Momen AA, Jelodar G, Dehdashti H. Brain magnetic resonance imaging findings in developmentally delayed children. Int J Pediatr. 2011;2011:386984. doi: 10.1155/2011/386984.
[10] Chaudhary K, Kashikar SV, Dhande RP. MRI assessment of paediatric developmental delay. J Evol Med Dent Sci. 2021 Feb 22;10(8):479-483. doi: 10.14260/jemds/2021/105.
[11] Ali AS, Syed NP, Murthy GSN, Nori M, Abkari A, Pooja BK, et al. Magnetic resonance imaging (MRI) evaluation of developmental delay in pediatric patients. J Clin Diagn Res. 2015 Jan;9(1):TC21-TC24. doi: 10.7860/JCDR/2015/11921.5478.
[12] Das T, Doddamani D, Katur AM, Kumar NA. Spectrum of magnetic resonance imaging brain findings in developmental delay in children below 5 years of age: an institutional study. MOJ Biol Med. 2024;9(2):73-77. doi: 10.15406/mojbm.2024.09.00219.
[13] Randhawa HS, Bagale S, Umap R, Randhawa J. Brain magnetic resonance imaging-based evaluation of pediatric patients with developmental delay: a cross-sectional study. Cureus. 2022 Apr 11;14(4):e24051. doi: 10.7759/cureus.24051.
[14] Elanchezhian, Kalaivani. MRI findings in children with global developmental delay. Int J Radiol Diagn Imaging. 2020;3(2):7-8. doi: 10.33545/26644436.2020.v3.i2a.89.
[15] Dittakavi LVPP, Tanneru S, Thanda P, Thomas SRJ. Role of magnetic resonance imaging brain in children with developmental delay. Int J Contemp Pediatr. 2023 Mar;10(3):305-310. doi: 10.18203/2349-3291.ijcp20230424.
[16] Balcha TE, Woldeyohannes AM, Neknek GA. Brain magnetic resonance imaging findings in patients with developmental delay in Addis Ababa, Ethiopia. Ethiop J Health Sci. 2022 Jul;32(4):773-780. doi: 10.4314/ejhs.v32i4.14.
[17] Abd Elghaffar TS, Abu Madyan NA, Metwaly NA, Selim LA. Role of brain magnetic resonance imaging in assessment of pediatric developmental delay. Med J Cairo Univ. 2020 Mar;88:115-124. doi: 10.21608/mjcu.2020.93968.
[18] Zeglam AM, Al-Ogab MF, Al-Shaftery T. MRI or not to MRI! Should brain MRI be a routine investigation in children with autistic spectrum disorders? Acta Neurol Belg. 2015 Sep;115(3):351-354. doi: 10.1007/s13760-014-0384-x.

Copyright *Author (s) 2026. Distributed under Creative Commons CC BY 4.0*
Received*: 17-09-2026 -* ***Accepted****: 15-11-2026 -* ***Published****: 24-11-2026*

[19] von Elm E, Altman DG, Egger M, Pocock SJ, Gøtzsche PC, Vandenbroucke JP; STROBE Initiative. The Strengthening the Reporting of Observational Studies in Epidemiology (STROBE) statement: guidelines for reporting observational studies. Lancet. 2007 Oct 20;370(9596):1453-1457. doi: 10.1016/S0140-6736(07)61602-X.
[20] Saunders DE, Thompson C, Gunny R, Jones R, Cox T, Chong WK. Magnetic resonance imaging protocols for paediatric neuroradiology. Pediatr Radiol. 2007 Aug;37(8):789-797. doi: 10.1007/s00247-007-0462-9.
[21] Kamble RB. Magnetic resonance imaging brain sequences in pediatrics. Karnataka Paediatr J. 2021;36(1):27-34.
[22] Halefoglu AM, Yousem DM. Susceptibility weighted imaging: clinical applications and future directions. World J Radiol. 2018 Apr 28;10(4):30-45. doi: 10.4329/wjr.v10.i4.30.
[23] Igra MS, Romanowski CAJ, Stivaros SM. Imaging of CSF spaces: anatomy, physiology, and hydrodynamics. In: Barkhof F, Jäger H, Thurnher M, Rovira À, editors. Clinical neuroradiology. Cham: Springer; 2019.
[24] Choudhri AF, editor. Pediatric neuroradiology: clinical practice essentials. New York: Thieme; 2016.
[25] Severino M, Geraldo AF, Utz N, Tortora D, Pogledic I, Klonowski W, et al. Definitions and classification of malformations of cortical development: practical guidelines. Brain. 2020 Oct 1;143(10):2874-2894. doi: 10.1093/brain/awaa174.
[26] Nguefack S, Fongue NN, Tague DAK, Kengne UIM, Tapouh JRM, Nguefack F, et al. Imaging of developmental delay in black African children: a hospital-based study in Yaoundé-Cameroon. Afr Health Sci. 2023 Mar;23(1):686-692. doi: 10.4314/ahs.v23i1.73.
[27] Rajvanshi N, Chacham S, Ks A, Semwal P, Nandolia KK, Rohilla J, et al. Magnetic resonance imaging brain yield in developmental delay: a developing country perspective. Res Dev Disabil. 2023 Jul;138:104518. doi: 10.1016/j.ridd.2023.104518.
[28] Volpe JJ. Brain injury in premature infants: a complex amalgam of destructive and developmental disturbances. Lancet Neurol. 2009 Jan;8(1):110-124. doi: 10.1016/S1474-4422(08)70294-1.
[29] Barkovich AJ, Norman D. Anomalies of the corpus callosum: correlation with further anomalies of the brain. AJNR Am J Neuroradiol. 1988 May-Jun;9(3):493-501.
[30] Barkovich AJ, Kjos BO, Jackson DE Jr, Norman D. Normal maturation of the neonatal and infant brain: MR imaging at 1.5 T. Radiology. 1988 Jan;166(1 Pt 1):173-180. doi: 10.1148/radiology.166.1.3336675.
[31] Murakami JW, Weinberger E, Shaw DW. Normal myelination of the pediatric brain imaged with fluid-attenuated inversion-recovery (FLAIR) MR imaging. AJNR Am J Neuroradiol. 1999 Sep;20(8):1406-1411.
[32] van der Knaap MS, Valk J. Magnetic resonance of myelination and myelin disorders. 3rd ed. Berlin: Springer; 2005.
[33] Gaillard F, Walizai T, Zhang B, et al. Normal myelination [Internet]. Radiopaedia.org; 2009 [updated 2025 Jun 9; cited 2026 Nov 6]. Available from: https://radiopaedia.org/articles/normal-myelination
[34] Ketonen LM, Hiwatashi A, Sidhu R, Westesson PL. Pediatric brain and spine: an atlas of MRI and spectroscopy. Berlin: Springer; 2005. doi: 10.1007/b137582.
[35] Dietrich RB, Bradley WG, Zaragoza EJ, Otto RJ, Taira RK, Wilson GH, et al. MR evaluation of early myelination patterns in normal and developmentally delayed infants. AJNR Am J Neuroradiol. 1988 Jan-Feb;9(1):69-76.
[36] Baron-Cohen S, Knickmeyer RC, Belmonte MK. Sex differences in the brain: implications for explaining autism. Science. 2005 Nov 4;310(5749):819-823. doi: 10.1126/science.1115455.
[37] Jacquemont S, Coe BP, Hersch M, Duyzend MH, Krumm N, Bergmann S, et al. A higher mutational burden in females supports a "female protective model" in neurodevelopmental disorders. Am J Hum Genet. 2014 Mar 6;94(3):415-425. doi: 10.1016/j.ajhg.2014.02.001.
[38] McCarthy MM, Arnold AP. Reframing sexual differentiation of the brain. Nat Neurosci. 2011 Jun;14(6):677-683.
[39] Stiles J, Jernigan TL. The basics of brain development. Neuropsychol Rev. 2010 Dec;20(4):327-348. doi: 10.1007/s11065-010-9148-4.
[40] Oishi K, Faria AV, Yoshida S, Chang L, Mori S. Quantitative evaluation of brain development using anatomical MRI and diffusion tensor imaging. Int J Dev Neurosci. 2013 Nov;31(7):512-524. doi: 10.1016/j.ijdevneu.2013.06.004.
[41] Parikh NA. Advanced neuroimaging and its role in predicting neurodevelopmental outcomes in very preterm infants. Semin Perinatol. 2016 Dec;40(8):530-541. doi: 10.1053/j.semperi.2016.09.002.
[42] Hua C, Wang XL, Sheng H. Neurodevelopmental disorders in children: the role of MRI in early detection and intervention planning. Front Neurosci. 2026;20:1758568. doi: 10.3389/fnins.2026.1758568.
[43] Veronese A, Osredkar D, Lovrečič L, Troha Gergeli A. Diagnostic approach to children with unexplained global developmental delay in pediatric neurology outpatient clinic. Neuropediatrics. 2025 Apr;56(2):125-132. doi: 10.1055/a-2430-0494.
[44] Vossough A. Newer MRI techniques in pediatric neuroimaging. Semin Roentgenol. 2023 Jan;58(1):131-144. doi: 10.1053/j.ro.2022.10.002.
[45] Battal B, Kocaoglu M, Bulakbasi N, Husmen G, Sanal HT, Tayfun C. Cerebrospinal fluid flow imaging by using phase-contrast MR technique. Br J Radiol. 2011 Aug;84(1004):758-765. doi: 10.1259/bjr/66206791.
[46] van Niekerk A, Svoboda J, Aspelin Å, Sprenger T, Rydén H, Norbeck O, et al. Awake pediatric brain-MRI: a fast multi-sequence scan augmented with motion compensated single-shot 2D acquisitions. Radiol Adv. 2024;1(1):umae010. doi: 10.1093/radadv/umae010.

Copyright *Author (s) 2026. Distributed under Creative Commons CC BY 4.0*
Received*: 17-09-2026 -* ***Accepted****: 15-11-2026 -* ***Published****: 24-11-2026*